E-ISSN 2250-0944
ISSN 2250-1150
doi: 10.48047/ijprt/16.02.92

Research Article

COMPARISON OF EFFICACY AND SAFETY OF ISOBARIC LEVOBUPIVACAINE WITH DIFERENT ADJUVANTS LIKE CLONIDINE VS DEXMEDETOMIDINE IN SEGMENTAL THORACIC SPINAL ANAESTHESIA FOR OPEN CHOLECYSTECTOMY CASES- A RANDOMIZED CASE CONTROL STUDY

Dr. Santhosh Kumar Bennur [1], Dr. Manasa G [2], Dr. Soumya M V[3], Dr. Darshan M S [4]

[1]Associate Professor, Department of Anaesthesiology, Chamarajnagar institute of medical sciences, Karnataka, India.
[2]Assistant Professor, Department of Anaesthesiology, Chamarajnagar institute of medical sciences, Karnataka. India.
[3]Associate Professor, Department of Anaesthesiology, Chamarajnagar institute of medical sciences, Karnataka, India.
[4]Associate Professor, Department of Anaesthesiology, Chamarajnagar institute of medical sciences, Karnataka, India.

Received Date: 21/05/2026 Accepted: 16/06/2026 Published Date:20/07/2026

Corresponding Author: Dr. Manasa G, Assistant Professor, Department of Anaesthesiology, Chamarajnagar institute of medical sciences, Karnataka. India.
Email: manasagopal555@gmail.com

ABSTRACT

Background: Thoracic segmental spinal anaesthesia (TSSA) is increasingly being used as an alternative to general anaesthesia for upper abdominal surgeries because it provides effective surgical anaesthesia, excellent postoperative analgesia, and enhanced recovery. Intrathecal α_2-adrenergic agonists such as clonidine and dexmedetomidine are commonly used as adjuvants to improve the quality and duration of spinal anaesthesia.

Aim: To compare the efficacy and safety of intrathecal clonidine and dexmedetomidine as adjuvants to isobaric levobupivacaine in thoracic segmental spinal anaesthesia for patients undergoing open cholecystectomy.

Methods: Sixty adult patients (ASA physical status I–II) scheduled for elective open cholecystectomy were randomly allocated into two equal groups (n = 30 each). Group C received isobaric levobupivacaine with clonidine, while Group D received isobaric levobupivacaine with dexmedetomidine for thoracic segmental spinal anaesthesia. The primary outcomes included onset and duration of sensory and motor blockade and time to first rescue analgesia. Secondary outcomes included haemodynamic parameters, sedation score, postoperative pain (VAS), rescue analgesic consumption, adverse effects.

Results: Baseline demographic characteristics were comparable between the groups ($p > 0.05$). Group D demonstrated a

significantly faster onset of sensory blockade, prolonged duration of sensory and motor block, delayed requirement for rescue analgesia, lower postoperative VAS scores, and reduced 24-hour analgesic consumption compared with Group C ($p < 0.05$). Sedation scores were significantly higher in Group D. The incidence of adverse effects was comparable between the groups, with no respiratory depression or neurological complications.

Conclusion: Dexmedetomidine is a superior intrathecal adjuvant to isobaric levobupivacaine when compared with clonidine for thoracic segmental spinal anaesthesia in open cholecystectomy. It provides longer postoperative analgesia, improved block characteristics, and an acceptable safety.

Keywords : segmental thoracic spinal anaesthesia, dexmedetomidine, clonidine, isobaric levobupivacaine.

INTRODUCTION

Open cholecystectomy is commonly performed for gallbladder diseases, particularly in patients unsuitable for laparoscopic procedures or in resource-limited settings. General anaesthesia remains the conventional technique; however, it is associated with airway manipulation, postoperative nausea and vomiting, opioid-related adverse effects, and delayed recovery, especially in high-risk patients[1].

Segmental thoracic spinal anaesthesia (STSA) has emerged as a safe and effective alternative for upper abdominal surgeries. By producing a selective blockade of the thoracic dermatomes involved in surgery, STSA provides adequate surgical anaesthesia with minimal sympathetic blockade, better haemodynamic stability, reduced respiratory complications, and early postoperative recovery[2]. Anatomical studies have demonstrated sufficient posterior cerebrospinal fluid space in the thoracic region, supporting the safety of this technique when performed by experienced anaesthesiologists[3].

Levobupivacaine, the S(-)-enantiomer of bupivacaine, offers a favourable safety profile with reduced cardiotoxicity and neurotoxicity while maintaining effective sensory blockade. Its isobaric formulation produces predictable segmental spread, making it particularly suitable for thoracic spinal anaesthesia[4].

Intrathecal α2-adrenergic agonists such as clonidine and dexmedetomidine are widely used as adjuvants to local anaesthetics to enhance the quality and duration of spinal blockade. Clonidine prolongs sensory blockade and postoperative analgesia but may be associated with hypotension and sedation at higher doses[5]. Dexmedetomidine, a more selective α2-agonist, has demonstrated superior analgesic efficacy, prolonged duration of blockade, and better patient satisfaction with minimal respiratory depression[6,7].

Although several studies have compared these agents in lumbar spinal anaesthesia, evidence regarding their efficacy and safety as adjuvants to isobaric levobupivacaine in segmental thoracic spinal anaesthesia for open cholecystectomy is limited. Therefore, the present study was undertaken to compare clonidine and dexmedetomidine with respect to analgesic efficacy, haemodynamic stability, and perioperative adverse effects in patients undergoing open cholecystectomy.

METHODS

After obtaining clearance from the Institutional Ethics Committee, this randomized comparative study was

conducted in the Department of Anesthesiology in Chamarajnagara institute of medical sciences, Chamarajanagar. The inclusion criteria included age between 18 and 60 years of either sex, being scheduled for an elective open cholecystectomy, the American Society of Anesthesiologists Status I and II. The exclusion criteria included patient denial for sub-arachnoid blocks, patient with bleeding disorder and cardiovascular disease; presence of infection in the site of block; known allergy to local anesthetic; patients with abnormalities of the spine (kyphosis or scoliosis).

After arrival in the operating room, an 18G IV cannula was inserted in a peripheral vein and infusion of balanced crystalloid solution was started. Patient's baseline vital parameters were recorded using pulse oxymeter, ECG and non-invasive blood pressure (NIBP). Patients were placed in sitting position and T10-T11 intervertebral space was identified. Under aseptic precautions and skin infiltration with (1% lignocaine) local anesthetics, a Quincke's babcock spinal needle 25G was placed in mid-line/paramedian approach. Correct placement was confirmed by free flow of clear CSF. Then,

Group C: 1.6 ml of 0.5% isobaric levobupivacine (5 mg) mixed with 0.2 ml of clonidine (30 microgram) was injected

Group D: 1.6 ml of 0.5% isobaric levobupivacine (5 mg) mixed with 0.2ml of dexmedetomidine (20 microgram) was injected and patients were placed in supine position immediately.

After that, clinical examination was done to assess the sensory and motor block along with heart rate, blood pressure, and SpO2. The vital parameters were recorded in regular interval until the end of surgery. The level of sensory block was assessed by pinprick, and motor block was assessed by modified Bromage scale for lower limb (0 = able to lift extended legs; 1 = just able to flex knees, full ankle movement; 2 = no knee movement, some ankle movement; 3 = complete paralysis). Once the block was considered adequate (minimum block T4–T12), and patients were sedated by 1 mg midazolam intravenously. All patients were given oxygen supplementation at 5 L/min with facemask. Adverse effects were treated accordingly e.g hypotension (MAP= lessthan70mmHg) with ephedrine, bradycardia (HR less than 50) with atropine as i.v. boluses as required, and nausea or vomiting was treated with Ondansetron 4 mg. After surgery, patients were transferred to the recovery room. The objectives of this study were intraoperative hemodynamic changes, perioperative complications, time of first rescue analgesic, total tramadol consumption in first 24 hours.

Statistical analysis: Collected data were analyzed using SPSS (Statistical Package for Social Sciences) for Windows, version23.0. Qualitative variables were expressed as frequency and percentages. Quantitative data were expressed in mean ± standard deviation. The results were presented using tables and figures.

RESULTS

This study was conducted among the 60 patients undergoing open cholecystectomy surgery. These 60 patients were randomly allocated in to Dexmedetomidine + levobupivacaine group (30 patients) and Clonidine + levobupivacaine group (30 patients).

Table 1: Demographic Characteristics.

Variable	Group C (n=30) Mean ± SD	Group D (n=30) Mean ± SD	p value
Age (years)	45.8 ± 10.1	46.4 ± 9.6	0.81
Weight (kg)	63.9 ± 7.8	64.7 ± 8.2	0.72
Height (cm)	160.9 ± 6.5	161.8 ± 5.8	0.58
BMI (kg/m²)	24.6 ± 2.9	24.8 ± 3.1	0.84
Male/Female	14/16	13/17	0.79

The two groups were comparable with respect to age, sex distribution, weight, height, and BMI. There were no statistically significant differences in baseline demographic variables ($p > 0.05$), comparable patient characteristics between the groups.

Table 2: Block Characteristics

Variable	Group C(n=30) Mean ± SD	Group D(n=30) Mean ± SD	p value
Onset of sensory block (min)	3.8 ± 0.9	2.9 ± 0.8	<0.001
Highest sensory level (Median)	T4	T4	0.99
Time to maximum block (min)	8.2 ± 1.6	6.9 ± 1.4	0.002
Duration of sensory block (min)	185 ± 22	223 ± 25	<0.001
Duration of motor block (min)	152 ± 19	180 ± 21	<0.001
Regression to T10 (min)	126 ± 16	149 ± 18	<0.001
Time to first rescue analgesia (min)	272 ± 40	356 ± 46	<0.001

Patients receiving dexmedetomidine (Group D) demonstrated a significantly faster onset of sensory block and reached the maximum sensory level earlier than those receiving clonidine (Group C). The duration of sensory block, motor block, regression to T10, and time to first rescue analgesia were all significantly prolonged in Group D ($p < 0.001$).

Hemodynamic Parameters

Table 3: Heart Rate (beats/min)

Time	Group D(Mean ± SD)	Group C (Mean ± SD)	p value
Baseline	82.4 ± 8.6	81.9 ± 7.9	0.84
5 min	79.2 ± 7.8	74.5 ± 7.4	0.02
10 min	77.6 ± 7.3	71.8 ± 6.8	0.003
20 min	76.4 ± 7.0	69.8 ± 6.5	0.001
30 min	75.8 ± 6.9	69.2 ± 6.2	0.001
60 min	76.6 ± 7.1	70.5 ± 6.4	0.002
End surgery	78.8 ± 7.6	73.4 ± 6.7	0.005

Baseline heart rate was comparable between the groups. Following spinal anesthesia, heart rate decreased in both groups; however, the reduction was significantly greater in the Clonidine group between 5 and 60 minutes ($p < 0.05$)

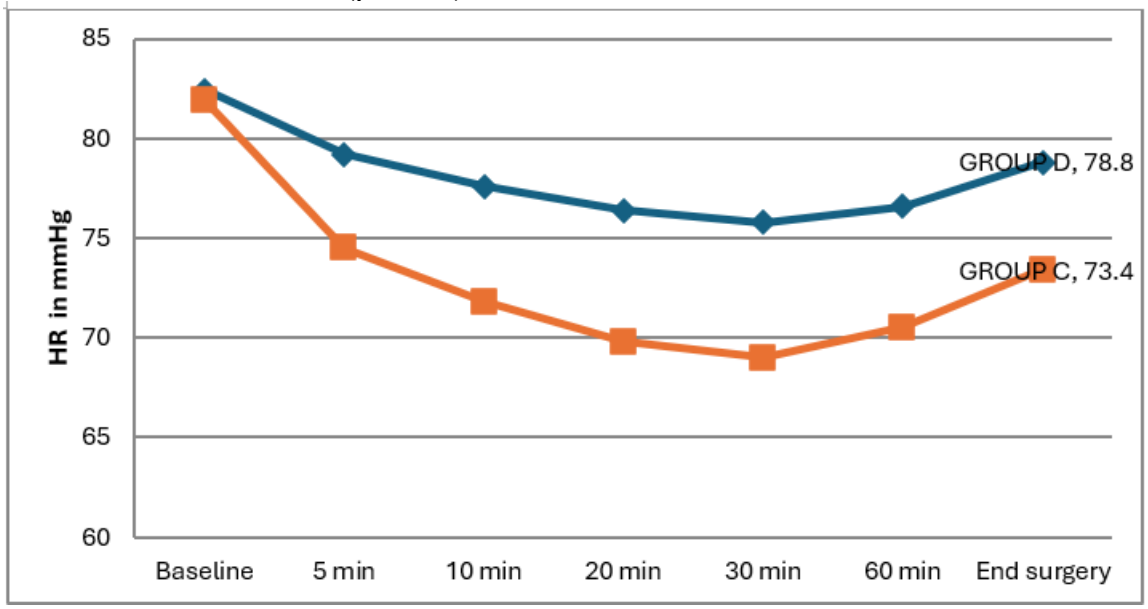

Figure 1: Comparison of HR between group D and group C

Table 4 :Mean Arterial Pressure (mmHg)

Time	Group D(n=30) Mean ± SD	Group C(n=30) Mean ± SD	p value
Baseline	96.5 ± 8.5	95.9 ± 8.2	0.79
5 min	90.8 ± 7.2	87.5 ± 7.6	0.09
10 min	88.2 ± 7.0	84.9 ± 7.2	0.07
20 min	87.6 ± 6.8	83.5 ± 6.9	0.03
30 min	88.5 ± 6.9	84.4 ± 7.1	0.04
60 min	90.6 ± 7.1	87.2 ± 7.3	0.08
End surgery	92.3 ± 7.4	89.5 ± 7.5	0.12

Mean arterial pressure decreased after administration of spinal anesthesia in both groups. The decrease was slightly greater in the Clonidine group, reaching statistical significance at 20 and 30 minutes.

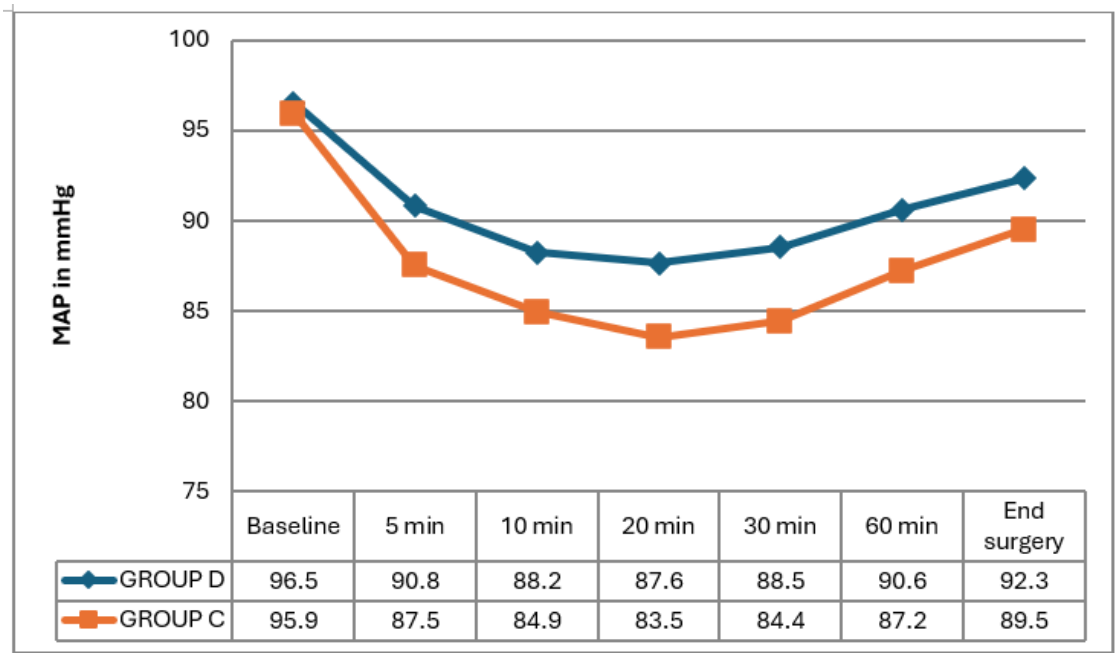

Figure 2: Comparison of MAP between group D and group C

Table 5: Sedation (Ramsay Sedation Score)

Variable	Group C(n=30) Mean ± SD	Group D(n=30) Mean ± SD	p value
Mean RSS	2.4 ± 0.5	3.2 ± 0.6	<0.001

The mean Ramsay Sedation Score was significantly higher in the dexmedetomidine group than in the clonidine group ($p < 0.001$). Patients remained calm, cooperative, and easily arousable, indicating that dexmedetomidine provided desirable intraoperative sedation without excessive drowsiness or respiratory depression.

Table 6: Pain Scores (VAS)

Time	Group C(n=30) Mean ± SD	Group D(n=30) Mean ± SD	p value
2 hours	1.2 ± 0.6	0.8 ± 0.5	0.01
4 hours	2.8 ± 0.9	1.7 ± 0.8	<0.001
6 hours	4.3 ± 1.1	2.8 ± 0.9	<0.001
8 hours	3.6 ± 1.0	2.9 ± 0.8	0.006
12 hours	2.8 ± 0.9	2.4 ± 0.8	0.09
24 hours	1.5 ± 0.6	1.4 ± 0.5	0.48

Pain scores were significantly lower in the dexmedetomidine group during the early postoperative period (2–8 hours). The difference gradually diminished by 12 and 24 hours. These findings suggest that dexmedetomidine provides superior early postoperative analgesia compared with clonidine.

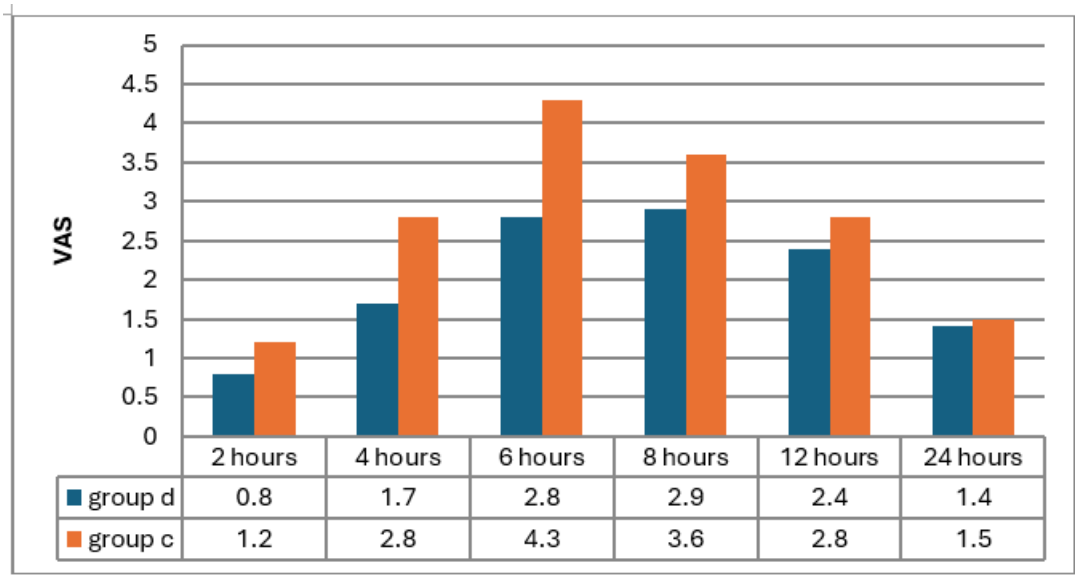

Figure 3: Comparison of VAS between group D and group C

Table 7: Rescue Analgesic Requirement

Variable	Group C(n=30) Mean ± SD	Group D(n=30) Mean ± SD	p value
Total Tramadol in 24 h (mg)	132 ± 34	86 ± 28	<0.001
Number requiring second dose	20 (66.7%)	10 (33.3%)	0.01

The time to first rescue analgesia was significantly longer in the dexmedetomidine group. In addition, total tramadol consumption over the first 24 hours was significantly lower, and fewer patients required a second rescue dose. These results confirm the prolonged analgesic effect of intrathecal dexmedetomidine.

Table 8: Adverse Effects

Complication	Group D n (%)	Group C n (%)	p value
Bradycardia	2 (6.7%)	5 (16.7%)	0.22
Hypotension	4 (13.3%)	6 (20.0%)	0.49
Nausea/Vomiting	2 (6.7%)	3 (16.7%)	0.23
Shivering	1 (3.3%)	3 (13.3%)	0.16
Respiratory depression	0	0	—
Pruritus	0	0	—
Neurological deficit	0	0	—

The incidence of adverse events, including bradycardia, hypotension, nausea, vomiting, and shivering, was comparable between the two groups, with no statistically significant differences. No patient experienced respiratory depression, pruritus, or neurological complications. This

indicates that both clonidine and dexmedetomidine are safe intrathecal adjuvants when used in appropriate doses.

DISCUSSION

The present randomized controlled study compared the efficacy and safety of intrathecal clonidine and dexmedetomidine as adjuvants to isobaric levobupivacaine in thoracic segmental spinal anaesthesia for patients undergoing open cholecystectomy. The principal findings were that dexmedetomidine produced a faster onset of sensory block, significantly prolonged sensory and motor block duration, delayed the requirement for rescue analgesia, improved intraoperative sedation, and reduced postoperative analgesic consumption compared with clonidine, while maintaining haemodynamic stability.

The demographic characteristics, including age, sex distribution, body weight, height, and body mass index, were comparable between the two study groups. The absence of statistically significant differences in baseline variables suggests successful randomization and minimizes the likelihood that patient-related factors influenced the observed outcomes. Similar baseline comparability has been reported in previous studies evaluating intrathecal α2-adrenergic agonists as adjuvants to levobupivacaine, thereby strengthening the internal validity of the present study[8,9]

One of the important findings of the present study was the significantly faster onset of sensory block in the dexmedetomidine group. This may be attributed to the higher α2-adrenoceptor selectivity of dexmedetomidine, which enhances local anaesthetic action by inhibiting the release of substance P and hyperpolarizing neurons within the dorsal horn of the spinal cord. Consequently, neuronal transmission is suppressed more effectively, resulting in earlier establishment of surgical anaesthesia. Similar findings have been reported by Gupta et al. and Arya et al., who demonstrated that intrathecal dexmedetomidine significantly reduced the onset time of sensory blockade compared with other adjuvants[9,10] .

The duration of sensory and motor blockade was significantly prolonged in patients receiving dexmedetomidine. This prolonged effect is explained by the synergistic interaction between dexmedetomidine and levobupivacaine, leading to enhanced inhibition of nociceptive pathways and prolonged spinal neuronal hyperpolarization. Prolonged blockade translated into significantly delayed regression of sensory block and a longer pain-free postoperative period. Similar observations have been reported in several randomized controlled trials and systematic reviews, which consistently concluded that dexmedetomidine is superior to clonidine in prolonging neuraxial blockade without increasing serious adverse effects[4,9,11] .

The time to first rescue analgesia was significantly longer and total postoperative tramadol consumption was significantly lower in the dexmedetomidine group. These findings indicate that dexmedetomidine provides prolonged postoperative analgesia, thereby reducing opioid requirements and their associated adverse effects. Improved postoperative analgesia is one of the major advantages of intrathecal α_2-agonists and has been consistently demonstrated in previous studies involving lower abdominal,

orthopaedic, and upper abdominal surgery[9,11] .

CONCLUSION

Dexmedetomidine is a superior intrathecal adjuvant to clonidine when combined with isobaric levobupivacaine for thoracic segmental spinal anaesthesia in open cholecystectomy. It provides longer postoperative analgesia, improved block characteristics, and an acceptable safety profile.

Financial support and sponsorship: Nil
Conflicts of interest: There are no conflicts of interest.

Acknowledgements: First and foremost I thank our institution for providing platform and opportunities for conducting this study and also for providing required equipment. I would like to thank statistical team for the analysis of the data. I thank the study subjects for taking part in the study and also thank our surgical colleagues for their support.

REFERENCES

1. Balavenkatasubramanian V, Senthilkumar K, Kumar V. Current indications for spinal anesthesia: a narrative review. Best Pract Res Clin Anaesthesiol. 2023;37(1):89-99.
2. le Roux JJ, Wakabayashi K, Jooma Z. Defining the role of thoracic spinal anaesthesia in the 21st century: a narrative review. Br J Anaesth. 2023;130(1):56-65.
3. Imbelloni LE, Quirici MB, Ferraz Filho JR, Cordeiro JA, Ganem EM. The anatomy of the thoracic spinal canal investigated with magnetic resonance imaging. Anesth Analg. 2010;110(5):1494-5.
4. Verma AK, Kumar N, Srinivas C, Sahu P. Comparison of isobaric and hyperbaric levobupivacaine in segmental thoracic spinal anaesthesia for cholecystectomy: a randomized study. Cureus. 2024;16:e76060.
5. Mahendru V, Tewari A, Katyal S, Grewal A, Singh MR, Katyal R. A comparison of intrathecal clonidine and dexmedetomidine as adjuvants to bupivacaine. J Anaesthesiol Clin Pharmacol. 2013;29(4):496-502.
6. Kanazi GE, Aouad MT, Jabbour-Khoury SI, Al Jazzar MD, Alameddine MM, Al-Yaman R, et al. Effect of low-dose dexmedetomidine or clonidine on the characteristics of bupivacaine spinal block. Acta Anaesthesiol Scand. 2006;50(2):222-7.
7. Manoharan MM, Nair AS, Kumar A. Dexmedetomidine versus clonidine as additives to levobupivacaine in spinal anaesthesia: a comparative study. Cureus. 2023;15(10):e46364.
8. Shatri G, Singh A. Thoracic Segmental Spinal Anesthesia. StatPearls Publishing; 2026.
9. Arya S, Singh B, Khalik M. Comparison of thoracic segmental spinal anesthesia using isobaric levobupivacaine with fentanyl versus dexmedetomidine in laparoscopic cholecystectomy. Cureus. 2026.
10. Gupta R, Verma R, Bogra J, Kohli M, Raman R, Kushwaha JK. A comparative study of intrathecal dexmedetomidine and fentanyl as adjuvants to bupivacaine. J Anaesthesiol Clin Pharmacol. 2011;27(3):339-43.
11. Abdallah FW, Brull R. Facilitatory effects of perineural and intrathecal dexmedetomidine on neuraxial and peripheral nerve blocks: a systematic review and meta-analysis. Br J Anaesth. 2013;110(6):915-925.
12. Elzohry AA, Hegab AS, Khalifa OY, et al. Safety and efficacy of ultrasound-guided combined segmental thoracic spinal epidural anesthesia in abdominal surgeries. Anesth Pain Med. 2023.
13. Imbelloni LE, Fornasari M, Fialho JC, Sant'Anna R, Cordeiro JA. Thoracic spinal

anesthesia for outpatient laparoscopic cholecystectomy: a prospective feasibility study. World J Surg. 2010;34(4):721-26.
14. Burlacu CL, Buggy DJ. Update on local anesthetics: focus on levobupivacaine. Ther Clin Risk Manag. 2008;4(2):381-92.
15. McLeod GA, Burke D. Levobupivacaine. Anaesthesia. 2001;56(4):331-41.
16. Al-Mustafa MM, Abu-Halaweh SA, Aloweidi AS, Murshidi MM, Ammari BA, Awwad ZM, et al. Effect of dexmedetomidine added to spinal bupivacaine for urological procedures. Saudi Med J. 2009;30(3):365-70.
17. Esmaoglu A, Turk S, Bayram A, Akin A, Ugur F, Ulgey A, et al. The effects of dexmedetomidine added to spinal levobupivacaine for gynecological surgery. J Clin Anesth. 2010;22(5):324-28.
18. El-Hennawy AM, Abd-Elwahab AM, Abd-Elmaksoud AM, El-Ozairy HS, Boulis SR. Addition of clonidine or dexmedetomidine to bupivacaine for pediatric caudal analgesia. Br J Anaesth. 2009;103(2):268-74.
19. Kallio A, Scheinin M, Koulu M, Ponkilainen R, Ruskoaho H, Viinamäki O, et al. Effects of dexmedetomidine, a selective alpha-2 adrenoceptor agonist, on haemodynamic control mechanisms. Clin Pharmacol Ther. 1989;46(1):33-42.