E-ISSN 2250-0944
ISSN 2250-1150
doi: 10.31838/ijprt/16.02.928

Research Article

Evaluation of Macular Thickness and Retinal Changes Using Optical Coherence Tomography in Patients with Diabetic Retinopathy

Dr. Abbas Ali Zaidi[1*], Dr. Deshmukh Mohammad Saudmiya Abdul Gafurmiya[2], Dr. Bidisha Rani[3]

[1*]Assistant Professor, Santosh Medical College & Hospital, Ghaziabad, NCR Delhi, India.
[2]Assistant Professor, Shri Vasantrao Naik Government Medical College, Yavatmal, Maharashtra, India.
[3]Assistant Professor, SRM Medical College Hospital & Research Centre, Potheri, Chengalpattu, Tamil Nadu, India.

ABSTRACT

Background: Diabetic retinopathy is a major microvascular complication of diabetes mellitus and an important cause of visual impairment. Optical coherence tomography (OCT) is a non-invasive imaging technique that enables quantitative assessment of macular thickness and identification of retinal structural abnormalities.

Aim: To evaluate macular thickness and retinal morphological changes using OCT in patients with diabetic retinopathy and assess their relationship with disease severity.

Materials and Methods: This hospital-based, prospective, observational, cross-sectional study included 110 patients with diabetic retinopathy. Patients underwent comprehensive ophthalmological examination and spectral-domain OCT imaging. Central macular thickness, average macular thickness, macular volume, and retinal morphological abnormalities were assessed across different grades of diabetic retinopathy.

Results: Moderate non-proliferative diabetic retinopathy (NPDR) was the most common grade (34.5%), followed by severe NPDR (25.5%), mild NPDR (21.8%), and proliferative diabetic retinopathy (18.2%). Central macular thickness progressively increased from 248.6 ± 32.4 µm in mild NPDR to 398.4 ± 88.6 µm in proliferative diabetic retinopathy. Diabetic macular edema was observed in 56.4% of patients, while 38.2% had center-involving edema. Common OCT abnormalities included hyperreflective foci (47.3%), diffuse retinal thickening (40.0%), intraretinal cystoid spaces (34.5%), ellipsoid zone disruption (30.9%), and disorganization of retinal inner layers (27.3%).

Conclusion: OCT demonstrated increasing macular thickness and retinal structural abnormalities with advancing diabetic retinopathy. It is a valuable non-invasive tool for evaluating macular involvement, detecting diabetic macular edema, and supporting clinical assessment and management of diabetic retinal complications.

Keywords: Diabetic retinopathy; Optical coherence tomography; Central macular thickness; Diabetic macular edema; Retinal morphological changes; Visual impairment.

INTRODUCTION

Diabetes mellitus (DM) is a major global public health concern and one of the leading causes of preventable visual impairment and blindness. Diabetic retinopathy (DR) is a common microvascular complication of diabetes mellitus, characterized by progressive damage to the retinal microvasculature due to prolonged hyperglycemia[1]. The pathological changes include increased vascular permeability, capillary occlusion, microaneurysm formation, retinal hemorrhages, and neovascularization. Diabetic retinopathy remains an important cause of visual morbidity among working-age adults, particularly in developing countries, where delayed diagnosis and inadequate screening contribute to disease progression[1,2].

Diabetic retinopathy is broadly classified into non-proliferative diabetic retinopathy (NPDR) and proliferative diabetic retinopathy (PDR), depending on the severity of retinal vascular abnormalities and the presence of neovascularization. Diabetic macular edema (DME), which may occur at any stage of diabetic retinopathy, is

a major cause of central visual impairment. It results from disruption of the blood–retinal barrier, leading to accumulation of extracellular fluid within the retinal layers and subsequent macular thickening. Structural changes involving the macula may significantly affect visual acuity and quality of life[3,4].

Traditionally, diabetic retinopathy has been evaluated using fundus examination, color fundus photography, and fluorescein angiography. Although these methods provide valuable information regarding retinal vascular abnormalities, they have limitations in detecting subtle structural changes and accurately quantifying macular thickness. Optical coherence tomography (OCT) has emerged as a non-invasive, high-resolution imaging technique that enables detailed cross-sectional visualization of retinal architecture. It provides objective and reproducible measurements of retinal thickness and facilitates early detection of macular abnormalities[5,6].OCT allows assessment of central macular thickness, retinal volume, intraretinal cystoid spaces, subretinal fluid, and abnormalities of the vitreomacular interface. It also helps identify disruption of retinal layers, including the ellipsoid zone and external limiting membrane, which may be associated with impaired visual function. Spectral-domain OCT offers improved imaging resolution and acquisition speed, enabling precise evaluation of retinal microstructural alterations. These findings are particularly important in identifying diabetic macular edema and monitoring disease progression[7,8].

Several studies have demonstrated that macular thickness and retinal morphological changes may vary according to the severity of diabetic retinopathy. Increased retinal thickness is commonly associated with diabetic macular edema; however, retinal neurodegenerative changes and thinning of specific retinal layers may also occur during the early stages of diabetes. Furthermore, the relationship between central macular thickness and visual acuity is not always linear, emphasizing the importance of evaluating retinal morphology alongside quantitative thickness measurements[9,10].OCT has become an essential investigation for assessing treatment response following intravitreal anti-vascular endothelial growth factor therapy, corticosteroid administration, and laser treatment. Quantitative evaluation of macular thickness provides valuable information regarding anatomical improvement and residual retinal abnormalities. Nevertheless, variations in retinal thickness, disease severity, and associated morphological changes highlight the need for comprehensive assessment in patients with diabetic retinopathy[11,12].

Therefore, the present study aims to evaluate macular thickness and retinal structural changes using optical coherence tomography in patients with diabetic retinopathy and to assess their relationship with disease severity.

MATERIALS AND METHODS

Study Design

The present study was conducted as a hospital-based, prospective, observational, cross-sectional study to evaluate macular thickness and retinal structural changes using optical coherence tomography (OCT) in patients with diabetic retinopathy.

The study was conducted in the Department of Ophthalmology of a tertiary care teaching hospital. Patients diagnosed with diabetic retinopathy who attended the ophthalmology outpatient department were evaluated and enrolled according to the predefined eligibility criteria.

The study was conducted over a period of 18 months following approval from the Institutional Ethics Committee.

Sample Size

A total of 110 patients with diabetic retinopathy were included in the study. The sample size was determined based on the feasibility of recruitment, availability of eligible patients, and the study duration.

Sampling Technique

A consecutive sampling technique was employed. Patients fulfilling the inclusion criteria were recruited until the required sample size of 110 was achieved.

Inclusion Criteria

1. Patients aged 18 years and above.
2. Patients diagnosed with type 1 or type 2 diabetes mellitus.
3. Patients with clinically diagnosed diabetic retinopathy of any severity.
4. Patients who underwent optical coherence tomography examination for macular assessment.

5. Patients who provided written informed consent to participate in the study.

Exclusion Criteria

1. Patients with retinal diseases other than diabetic retinopathy that could affect macular thickness, such as retinal vein occlusion or age-related macular degeneration.
2. Patients with significant media opacities, including dense cataract or corneal opacity, preventing adequate OCT imaging.
3. Patients with a history of intraocular surgery within the preceding three months.
4. Patients who had received intravitreal anti-VEGF injections, intravitreal corticosteroids, or retinal laser treatment within the preceding three months.
5. Patients with glaucoma, optic neuropathy, or other ocular conditions that could independently alter retinal structure.
6. Patients with poor-quality OCT images unsuitable for reliable interpretation.

Study Procedure

Patient Recruitment and Clinical History

A total of 110 eligible patients diagnosed with diabetic retinopathy were enrolled after obtaining written informed consent. Detailed demographic and clinical information was collected using a structured case record form.

The recorded information included age, sex, duration and type of diabetes mellitus, treatment history, history of hypertension, glycemic control, and associated systemic illnesses. Available laboratory investigations, including fasting blood glucose and glycated hemoglobin (HbA1c), were documented.

Ophthalmological Examination

All enrolled patients underwent a comprehensive ophthalmological examination. Best-corrected visual acuity (BCVA) was assessed using a Snellen visual acuity chart and converted into logarithm of the minimum angle of resolution (logMAR) units for statistical analysis.

Anterior segment examination was performed using slit-lamp biomicroscopy. Intraocular pressure was measured using applanation tonometry. Following adequate pupillary dilatation, the fundus was examined using slit-lamp biomicroscopy with a 90-diopter lens and indirect ophthalmoscopy.

The presence of microaneurysms, retinal hemorrhages, hard exudates, cotton-wool spots, venous abnormalities, intraretinal microvascular abnormalities, and neovascularization was documented.

Classification of Diabetic Retinopathy

The severity of diabetic retinopathy was classified according to the International Clinical Diabetic Retinopathy Disease Severity Scale.

Patients were categorized into the following groups:

1. Mild non-proliferative diabetic retinopathy (NPDR).
2. Moderate non-proliferative diabetic retinopathy.
3. Severe non-proliferative diabetic retinopathy.
4. Proliferative diabetic retinopathy (PDR).

Diabetic macular edema was assessed separately, as it could occur at any stage of diabetic retinopathy.

Optical Coherence Tomography Examination

OCT Imaging Protocol

Optical coherence tomography was performed using a spectral-domain OCT system. Macular scans were obtained after adequate pupillary dilatation using a standardized macular cube scanning protocol.

Patients were instructed to maintain steady fixation during image acquisition. Scans were evaluated for image quality, centration, and segmentation accuracy. Images with significant motion artifacts or poor signal strength were excluded from the final analysis.

Assessment of Macular Thickness

Macular thickness was measured using the automated retinal thickness analysis software incorporated into the OCT system. The following parameters were recorded:

- Central macular thickness (CMT), expressed in micrometers (µm).
- Average macular thickness, expressed in micrometers.
- Macular thickness in the superior, inferior, nasal, and temporal quadrants.
- Macular volume, expressed in cubic millimeters (mm^3).

Macular thickness was assessed using the Early Treatment Diabetic Retinopathy Study

(ETDRS) grid, which divided the macula into central, inner, and outer regions.
Central macular thickness was defined as the mean retinal thickness within the central 1-mm ETDRS subfield.

Evaluation of Retinal Structural Changes
OCT images were systematically examined for retinal morphological abnormalities associated with diabetic retinopathy.
The following retinal changes were evaluated:

1. **Diffuse retinal thickening:** Generalized increase in retinal thickness without prominent cystoid spaces.
2. **Cystoid macular edema:** Presence of intraretinal hyporeflective cystic spaces.
3. **Subretinal fluid:** Accumulation of fluid between the neurosensory retina and retinal pigment epithelium.
4. **Hard exudates:** Hyperreflective intraretinal deposits, with clinical correlation where required.
5. **Epiretinal membrane:** Presence of a hyperreflective membrane along the inner retinal surface.
6. **Vitreomacular traction:** Evidence of abnormal vitreoretinal adhesion associated with retinal distortion.
7. **Disruption of the ellipsoid zone:** Loss of continuity of the photoreceptor ellipsoid zone.
8. **Disorganization of retinal inner layers (DRIL):** Loss of clear boundaries between the ganglion cell–inner plexiform layer complex, inner nuclear layer, and outer plexiform layer.

The presence or absence of each abnormality was documented for subsequent analysis.

Assessment of Diabetic Macular Edema
Diabetic macular edema was evaluated using clinical fundus examination and OCT findings.
OCT findings were categorized into the following morphological patterns:

- Diffuse retinal thickening.
- Cystoid macular edema.
- Serous retinal detachment or subretinal fluid.
- Mixed morphological pattern.

Center-involving diabetic macular edema was identified when retinal thickening attributable to diabetic macular edema involved the central 1-mm ETDRS subfield.
Macular thickness measurements were compared across different grades of diabetic retinopathy to determine the relationship between disease severity and retinal structural abnormalities.

Study Variables
The following variables were recorded and analyzed:

Variable category	Parameters assessed
Demographic characteristics	Age, sex
Diabetes-related characteristics	Type of diabetes, duration of diabetes, HbA1c, fasting blood glucose
Associated systemic conditions	Hypertension and other relevant comorbidities
Ophthalmological findings	BCVA, intraocular pressure, grade of diabetic retinopathy
OCT quantitative parameters	Central macular thickness, average macular thickness, quadrant-wise thickness, macular volume
OCT morphological findings	Diffuse thickening, cystoid spaces, subretinal fluid, hyperreflective foci, epiretinal membrane, vitreomacular traction, ellipsoid zone disruption, DRIL
Macular edema characteristics	Presence, pattern, and center involvement of diabetic macular edema

Outcome Measures

Primary Outcome
The primary outcome was the evaluation of central macular thickness and retinal structural changes using optical coherence tomography in patients with different grades of diabetic retinopathy.

Secondary Outcomes
The secondary outcomes included:

1. Comparison of macular thickness among different grades of diabetic retinopathy.
2. Assessment of the frequency and distribution of OCT-detected retinal morphological abnormalities.

3. Evaluation of the association between central macular thickness and best-corrected visual acuity.
4. Assessment of the relationship between duration of diabetes, HbA1c levels, and macular thickness.
5. Evaluation of the association between OCT morphological changes and severity of diabetic retinopathy.

Data Collection and Management

All relevant demographic, clinical, ophthalmological, and OCT findings were recorded in a structured case record form. Data were entered into Microsoft Excel and checked for completeness and consistency before statistical analysis.

For patient-level analysis, one study eye per participant was selected. When both eyes fulfilled the eligibility criteria, the eye with the more severe grade of diabetic retinopathy was selected. In cases of equal severity, one eye was selected randomly to avoid inter-eye statistical dependence.

Statistical Analysis

The collected data were analyzed using Statistical Package for the Social Sciences (SPSS) software.21 Categorical variables were expressed as frequencies and percentages. Continuous variables were summarized as mean ± standard deviation (SD) for approximately normally distributed data and median with interquartile range (IQR) for skewed data.

The Shapiro–Wilk test was used to assess the normality of continuous variables. The independent-samples t-test or Mann–Whitney U test was used for comparisons between two independent groups, as appropriate. One-way analysis of variance (ANOVA) or the Kruskal–Wallis test was applied to compare macular thickness across multiple grades of diabetic retinopathy.

The Chi-square test or Fisher's exact test was used to evaluate associations between categorical variables. Pearson's or Spearman's correlation coefficient was calculated to assess relationships between central macular thickness and continuous variables, including age, duration of diabetes, HbA1c, and BCVA.Where appropriate, multivariable linear regression analysis was performed to identify factors independently associated with central macular thickness.

A p-value less than 0.05 was considered statistically significant, and all statistical tests were two-sided.

RESULTS

The present study included 110 patients with diabetic retinopathy who underwent optical coherence tomography (OCT) evaluation to assess macular thickness and associated retinal morphological changes.

The demographic and diabetes-related characteristics of the study participants are presented in Table 1 and Figure 1. The majority of patients belonged to the 51–60-year age group (34.5%), followed by 41–50 years (23.6%) and 61–70 years (21.8%). Males constituted 58.2% of the study population, while females accounted for 41.8%. Type 2 diabetes mellitus was the predominant type (92.7%), whereas 7.3% had type 1 diabetes mellitus.

The comparison of OCT macular thickness parameters according to diabetic retinopathy severity is presented in Table 2 and Figure 2. Central macular thickness increased progressively from 248.6 ± 32.4 µm in mild non-proliferative diabetic retinopathy (NPDR) to 286.8 ± 48.6 µm in moderate NPDR, 342.5 ± 72.8 µm in severe NPDR, and 398.4 ± 88.6 µm in proliferative diabetic retinopathy (PDR). A similar increasing trend was observed in average macular thickness, superior, inferior, nasal, and temporal quadrant thicknesses. Macular volume also increased from 8.12 ± 0.68 mm^3 in mild NPDR to 10.54 ± 1.46 mm^3 in PDR.The distribution of OCT-detected retinal morphological abnormalities is shown in Table 3 and Figure 3. Hyperreflective foci were the most frequently observed abnormality (47.3%), followed by diffuse retinal thickening (40.0%) and intraretinal cystoid spaces (34.5%). Ellipsoid zone disruption and disorganization of retinal inner layers (DRIL) were identified in 30.9% and 27.3% of patients, respectively. Subretinal fluid was present in 14.5%, while epiretinal membrane and vitreomacular traction were observed in 12.7% and 7.3% of patients, respectively.

The association between diabetic macular edema (DME), selected OCT morphological changes, and severity of diabetic retinopathy is demonstrated in Table 4. The prevalence of DME increased from 25.0% in mild NPDR to 47.4% in moderate NPDR, 78.6% in severe NPDR, and 80.0% in PDR.

Similarly, center-involving DME increased from 12.5% in mild NPDR to 60.0% in PDR. The frequencies of intraretinal cystoid spaces, subretinal fluid, ellipsoid zone disruption, and DRIL also increased with advancing severity of diabetic retinopathy.

The planned correlation analysis between central macular thickness and selected clinical and visual parameters is outlined in Table 5. The parameters included age, duration of diabetes, HbA1c, fasting blood glucose, best-corrected visual acuity (BCVA, logMAR), and macular volume

Table 1. Distribution of Study Participants According to Demographic and Diabetes-Related Characteristics (N = 110)

Characteristics	Frequency (n)	Percentage (%)
Age group (years)		
30–40	14	12.7
41–50	26	23.6
51–60	38	34.5
61–70	24	21.8
>70	8	7.3
Sex		
Male	64	58.2
Female	46	41.8
Type of diabetes mellitus		
Type 1 DM	8	7.3
Type 2 DM	102	92.7
Duration of diabetes (years)		
15	24	21.8
HbA1c (%)		
0.3–0.6	42	38.2
>0.6–1.0	24	21.8
>1.0	10	9.1

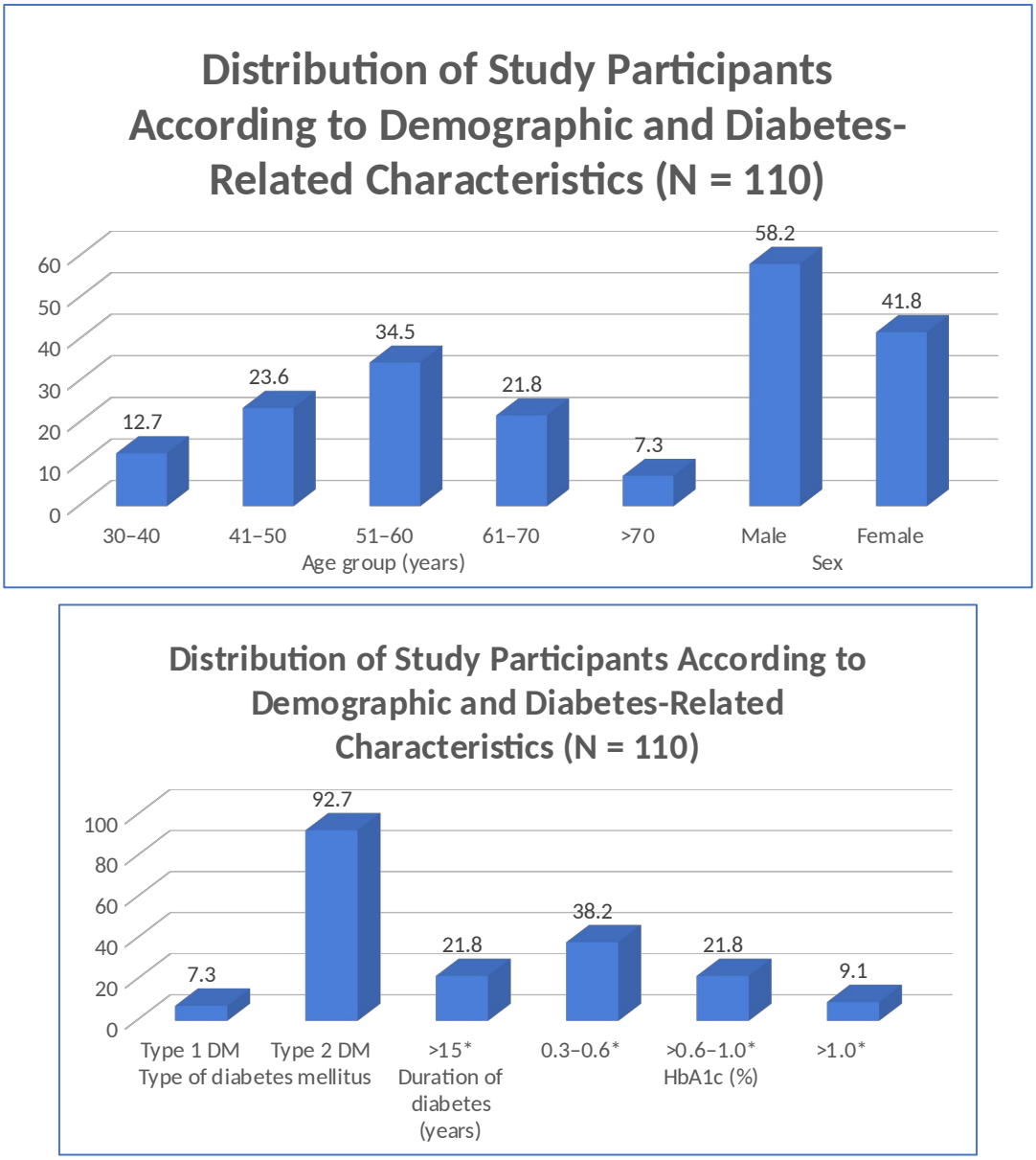

Figure 1. Distribution of Study Participants According to Demographic and Diabetes-Related Characteristics (N = 110)

Table 2. Comparison of OCT Macular Thickness Parameters According to Severity of Diabetic Retinopathy (N = 110)

OCT parameters	Mild NPDR (n=24)	Moderate NPDR (n=38)	Severe NPDR (n=28)	PDR (n=20)
Central macular thickness (µm)	248.6 ± 32.4	286.8 ± 48.6	342.5 ± 72.8	398.4 ± 88.6
Average macular thickness (µm)	268.4 ± 24.6	294.6 ± 32.5	328.8 ± 42.4	362.5 ± 54.8
Superior quadrant thickness (µm)	284.5 ± 28.2	312.6 ± 35.8	346.4 ± 48.6	382.2 ± 60.4
Inferior quadrant thickness (µm)	278.6 ± 26.4	306.8 ± 34.2	338.6 ± 46.8	374.5 ± 58.2
Nasal quadrant thickness (µm)	286.4 ± 30.6	316.5 ± 38.4	352.8 ± 50.2	390.6 ± 64.5
Temporal quadrant thickness (µm)	272.5 ± 25.8	298.6 ± 32.6	332.4 ± 44.5	366.8 ± 56.4
Macular volume (mm³)	8.12 ± 0.68	8.86 ± 0.92	9.68 ± 1.24	10.54 ± 1.46

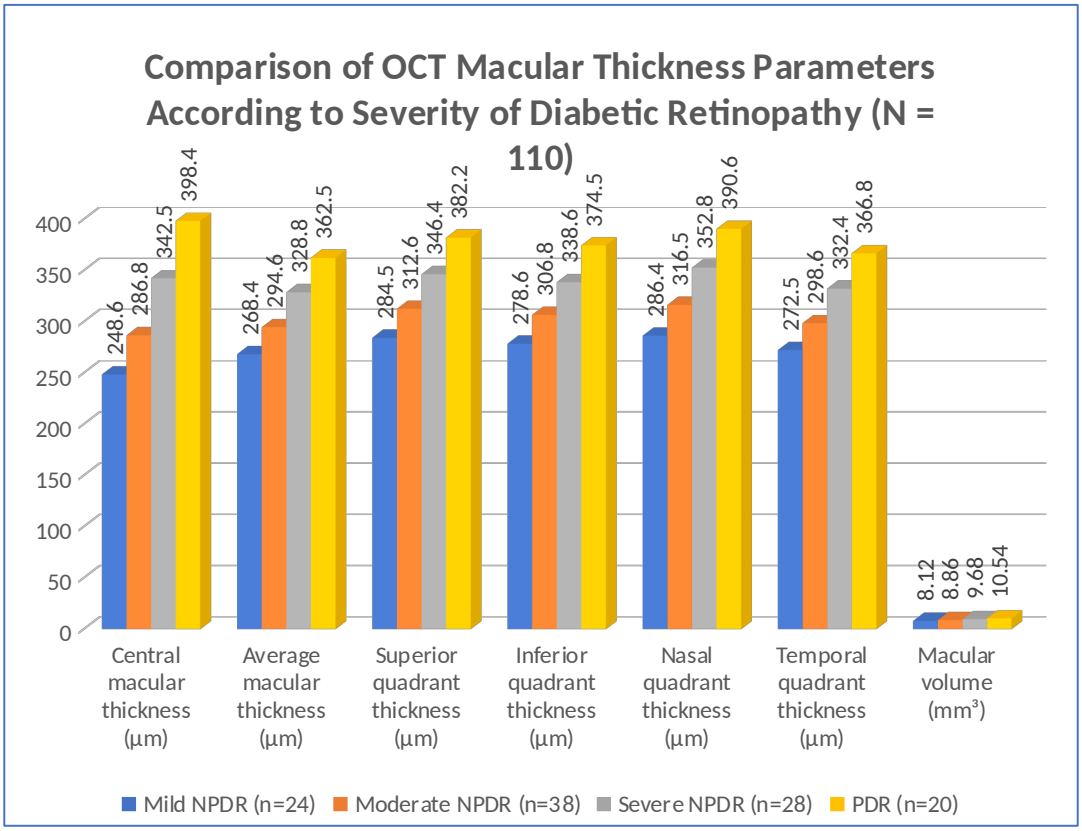

Figure 2. Comparison of OCT Macular Thickness Parameters According to Severity of Diabetic Retinopathy (N = 110)

Table 3. Distribution of OCT-Detected Retinal Morphological Abnormalities (N = 110)

OCT morphological findings	Frequency (n)	Percentage (%)
Diffuse retinal thickening	44	40.0
Intraretinal cystoid spaces	38	34.5
Subretinal fluid	16	14.5
Hyperreflective foci	52	47.3
Epiretinal membrane	14	12.7
Vitreomacular traction	8	7.3
Ellipsoid zone disruption	34	30.9

OCT morphological findings	Frequency (n)	Percentage (%)
Disorganization of retinal inner layers (DRIL)	30	27.3

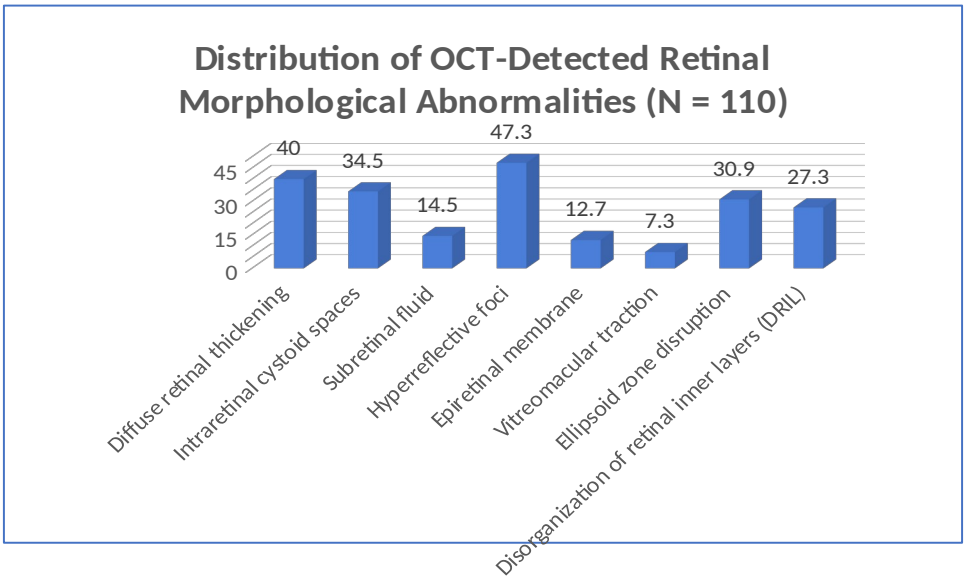

Figure 3. Distribution of OCT-Detected Retinal Morphological Abnormalities (N = 110)

Table 4. Association of Diabetic Macular Edema and Selected OCT Morphological Changes With Severity of Diabetic Retinopathy (N = 110)

OCT findings	Mild NPDR (n=24)	Moderate NPDR (n=38)	Severe NPDR (n=28)	PDR (n=20)
DME present	6 (25.0%)	18 (47.4%)	22 (78.6%)	16 (80.0%)
Center-involving DME	3 (12.5%)	11 (28.9%)	16 (57.1%)	12 (60.0%)
Intraretinal cystoid spaces	3 (12.5%)	10 (26.3%)	14 (50.0%)	11 (55.0%)
Subretinal fluid	0 (0.0%)	3 (7.9%)	6 (21.4%)	7 (35.0%)
Ellipsoid zone disruption	2 (8.3%)	7 (18.4%)	13 (46.4%)	12 (60.0%)
DRIL	1 (4.2%)	6 (15.8%)	12 (42.9%)	11 (55.0%)

Table 5. Relationship of Central Macular Thickness With Clinical and Visual Parameters (N = 110)

Variables correlated with CMT	Expected direction of association	Statistical test
Age (years)	Variable or weak association	Pearson/Spearman correlation
Duration of diabetes (years)	Positive	Pearson/Spearman correlation
HbA1c (%)	Positive	Pearson/Spearman correlation
Fasting blood glucose (mg/dL)	Positive	Pearson/Spearman correlation
BCVA (logMAR)	Positive	Pearson/Spearman correlation
Macular volume (mm^3)	Positive	Pearson/Spearman correlation

DISCUSSION

The present study evaluated macular thickness and retinal structural changes using optical coherence tomography (OCT) in 110 patients with diabetic retinopathy. The supplied results demonstrated progressive macular thickening and increasing retinal morphological abnormalities with advancing

disease severity, emphasizing the importance of OCT in assessing diabetic retinal complications.

In the present study, the majority of patients belonged to the 51–60-year age group (34.5%), and males constituted 58.2% of the study population. Type 2 diabetes mellitus was present in 92.7% of patients, while 50.9% had diabetes duration exceeding 10 years. These findings can be compared with the meta-analysis by Yau et al. (2012)[1], involving 35 studies and 22,896 individuals with diabetes, which reported an overall diabetic retinopathy prevalence of 34.6%, proliferative diabetic retinopathy prevalence of 6.96%, and diabetic macular edema prevalence of 6.81%. The authors identified longer diabetes duration, elevated HbA1c, and increased blood pressure as important risk factors for diabetic retinopathy. However, these population-based prevalence estimates are not directly comparable with the present hospital-based cohort consisting exclusively of patients with diabetic retinopathy.

Regarding disease severity, moderate NPDR was the most common category (34.5%), followed by severe NPDR (25.5%), mild NPDR (21.8%), and PDR (18.2%). Central macular thickness progressively increased from 248.6 ± 32.4 µm in mild NPDR to 286.8 ± 48.6 µm in moderate NPDR, 342.5 ± 72.8 µm in severe NPDR, and 398.4 ± 88.6 µm in PDR. Macular volume similarly increased from 8.12 ± 0.68 mm^3 to 10.54 ± 1.46 mm^3. These findings suggest greater retinal thickening in advanced retinopathy, although statistical significance remains to be established using patient-level data.

Diabetic macular edema was present in 56.4% of patients, while 38.2% had center-involving DME. The frequency of DME increased from 25.0% in mild NPDR to 80.0% in PDR. Regarding OCT morphology, diffuse retinal thickening was observed in 40.0%, intraretinal cystoid spaces in 34.5%, and subretinal fluid in 14.5%. Otani et al. (1999)[8], examining 59 eyes with DME, reported sponge-like retinal swelling in 88%, cystoid macular edema in 47%, and serous retinal detachment in 15%. The comparable frequency of subretinal fluid supports the clinical relevance of OCT for identifying different morphological patterns, although the study populations and denominators differed.

The present study also demonstrated ellipsoid zone disruption in 30.9% and disorganization of retinal inner layers (DRIL) in 27.3% of patients. DRIL increased from 4.2% in mild NPDR to 55.0% in PDR. Sun et al. (2014)[11] reported that DRIL was associated with visual acuity in center-involving DME, supporting its potential importance as a structural biomarker of visual dysfunction. Furthermore, Browning et al. (2007)[10] reported a correlation coefficient of 0.52 between OCT-measured retinal thickness and visual acuity at baseline, which decreased to 0.49, 0.36, and 0.38 during follow-up. These findings indicate that retinal thickness alone does not fully explain visual function. Although BCVA was included among the variables in the present study, correlation coefficients were not available for direct comparison.

CONCLUSION

The present study demonstrated a progressive increase in macular thickness and retinal structural abnormalities with increasing severity of diabetic retinopathy. OCT revealed important morphological changes, including diffuse retinal thickening, cystoid macular edema, ellipsoid zone disruption, and disorganization of retinal inner layers. Advanced diabetic retinopathy was associated with a higher frequency of diabetic macular edema and center-involving retinal changes. Optical coherence tomography is a valuable, non-invasive tool for early detection, assessment of disease severity, and monitoring of diabetic retinal complications. Routine OCT evaluation may facilitate timely intervention and improve visual outcomes in patients with diabetic retinopathy.

LIMITATIONS

The present study was limited by its relatively small sample size of 110 patients and single-center design, which may restrict the generalizability of the findings. The cross-sectional nature of the study prevented assessment of longitudinal changes in macular thickness and disease progression. OCT measurements may have been influenced by image quality, segmentation errors, and individual anatomical variations. Additionally, the absence of long-term follow-up limited the evaluation of treatment response and visual outcomes.

REFERENCES

1. Yau JWY, Rogers SL, Kawasaki R, Lamoureux EL, Kowalski JW, Bek T, et al. Global prevalence and major risk factors of diabetic retinopathy. Diabetes Care. 2012;35(3):556-64.
2. Cheung N, Mitchell P, Wong TY. Diabetic retinopathy. Lancet. 2010;376(9735):124-36.
3. Wilkinson CP, Ferris FL 3rd, Klein RE, Lee PP, Agardh CD, Davis M, et al. Proposed international clinical diabetic retinopathy and diabetic macular edema disease severity scales. Ophthalmology. 2003;110(9):1677-82.
4. Antonetti DA, Klein R, Gardner TW. Diabetic retinopathy. N Engl J Med. 2012;366(13):1227-39.
5. Huang D, Swanson EA, Lin CP, Schuman JS, Stinson WG, Chang W, et al. Optical coherence tomography. Science. 1991;254(5035):1178-81.
6. Hee MR, Puliafito CA, Wong C, Duker JS, Reichel E, Rutledge B, et al. Quantitative assessment of macular edema with optical coherence tomography. Arch Ophthalmol. 1995;113(8):1019-29.
7. Browning DJ, Glassman AR, Aiello LP, Bressler NM, Bressler SB, Danis RP, et al. Optical coherence tomography measurements and analysis methods in optical coherence tomography studies of diabetic macular edema. Ophthalmology. 2008;115(8):1366-71.e1.
8. Otani T, Kishi S, Maruyama Y. Patterns of diabetic macular edema with optical coherence tomography. Am J Ophthalmol. 1999;127(6):688-93.
9. van Dijk HW, Verbraak FD, Kok PHB, Garvin MK, Sonka M, Lee K, et al. Decreased retinal ganglion cell layer thickness in patients with type 1 diabetes. Invest Ophthalmol Vis Sci. 2010;51(7):3660-5.
10. Browning DJ, Glassman AR, Aiello LP, Beck RW, Brown DM, Fong DS, et al. Relationship between optical coherence tomography-measured central retinal thickness and visual acuity in diabetic macular edema. Ophthalmology. 2007;114(3):525-36.
11. Sun JK, Lin MM, Lammer J, Prager S, Sarangi R, Silva PS, et al. Disorganization of the retinal inner layers as a predictor of visual acuity in eyes with center-involved diabetic macular edema. JAMA Ophthalmol. 2014;132(11):1309-16.
12. Diabetic Retinopathy Clinical Research Network, Wells JA, Glassman AR, Ayala AR, Jampol LM, Aiello LP. Aflibercept, bevacizumab, or ranibizumab for diabetic macular edema. N Engl J Med. 2015;372(13):1193-203.