E-ISSN 2250-0944
ISSN 2250-1150
doi: 10.31838/ijprt/16.02.966

Research Article

Hepatoprotective Effects of Methanolic Clitoria Ternatea Extract in Ethanol-Exposed Wistar Rats: Biochemical and Histopathological Assessment

Astha Verma[1], Gautam Gehani[2]
[1]Research Scholar, Mittal Institute of Pharmacy, Bhopal, India.
[2]Assistant professor, Mittal Institute of Pharmacy, Bhopal, India.
Email: [1]aashthaverma03@gmail.com, [2]gautamgehani13595@gmail.com
Received: 26.09.26, Revised: 21.10.26, Accepted: 26.11.26

ABSTRACT
Background: Ethanol-associated hepatic injury is linked to oxidative and metabolic stress, and plant-derived preparations are being investigated as potential sources of hepatoprotective compounds. Clitoria ternatea L. (Fabaceae) contains several reported classes of secondary metabolites, but the activity of a specific extract depends on the plant part, extraction procedure and chemical composition. This study evaluated the effects of a methanolic C. ternatea extract in an ethanol-induced rat model using serum biochemical markers and liver histopathology.
Methods: Plant material collected in Bhopal, Madhya Pradesh, India, was shade-dried, powdered and extracted with methanol using Soxhlet extraction. Thirty male Wistar rats were allocated to five groups (n=6): vehicle control, ethanol control (1 mL/kg, orally), ethanol plus silymarin (100 mg/kg), and ethanol plus C. ternatea extract at 200 or 400 mg/kg. The experimental period was 14 days. Serum SGPT/ALT, SGOT/AST, alkaline phosphatase (ALP) and total bilirubin were measured. Liver sections were processed for haematoxylin-and-eosin staining.
Results: Extraction of 278.89 g plant material yielded 20.78 g crude extract (7.45%). Ethanol exposure was associated with increased SGPT (97.54 ± 2.28 U/L), SGOT (134.43 ± 2.02 U/L), ALP (210.64 ± 3.22 U/L) and total bilirubin (1.21 ± 0.09 mg/dL), relative to vehicle controls. The 200 and 400 mg/kg extract groups showed lower values for all four markers: SGPT, 68.36 ± 1.76 and 54.73 ± 1.59 U/L; SGOT, 90.61 ± 1.73 and 78.13 ± 1.51 U/L; ALP, 173.46 ± 2.82 and 137.92 ± 2.54 U/L; and bilirubin, 0.55 ± 0.05 and 0.47 ± 0.04 mg/dL, respectively. One-way ANOVA indicated an overall group effect for each marker ($P<0.001$). Histological descriptions in the source record indicated severe injury in the ethanol group and better-preserved hepatic architecture in the 400 mg/kg group.
Conclusion: Under the conditions reported, methanolic C. ternatea extract was associated with partial improvement in serum markers and qualitative liver histology after ethanol exposure, with the 400 mg/kg dose showing greater improvement than 200 mg/kg. These findings are preliminary: extract standardization, detailed dosing chronology, blinded quantitative histopathology and mechanistic endpoints were not documented and are needed before efficacy or mechanism can be established.

Keywords: Clitoria Ternatea, Butterfly Pea, Ethanol-Induced Hepatotoxicity, Hepatoprotection, Wistar Rats, Alanine Aminotransferase, Aspartate Aminotransferase, Histopathology.

INTRODUCTION

The liver is a central metabolic and detoxification organ and is continuously exposed to compounds absorbed from the gastrointestinal tract. Its hepatocytes carry out nutrient metabolism, bile production, plasma-protein synthesis and biotransformation of endogenous and exogenous chemicals. These functions also make the liver vulnerable to injury when metabolism generates reactive intermediates or when exposure overwhelms cellular defence systems [1].

Alcohol-associated liver disease comprises a spectrum of pathological changes, from steatosis to steatohepatitis, fibrosis and cirrhosis. Ethanol is metabolized primarily through alcohol dehydrogenase, with contributions from catalase and the microsomal ethanol-oxidizing system. CYP2E1 induction during sustained ethanol exposure can increase reactive oxygen species generation and lipid peroxidation, contributing to hepatocellular injury. Oxidative stress, mitochondrial dysfunction, inflammatory signalling and altered lipid handling are interrelated components of alcohol-associated liver injury [2-4].

Serum aminotransferases are widely used indicators of hepatocellular injury. ALT (historically reported as SGPT) and AST (SGOT) can increase when hepatocyte membrane integrity is compromised. ALP and bilirubin provide complementary information about hepatobiliary function and excretory disturbance. These markers are not, by themselves, specific measures of the underlying mechanism;

interpretation is strengthened when biochemical findings are considered alongside tissue morphology and additional mechanistic endpoints [5-7].

Clitoria ternatea L., commonly known as butterfly pea or Aparajita, is a perennial member of the Fabaceae. Different plant parts have been used in traditional systems and have been investigated for diverse biological activities. Reported constituents across the species include anthocyanins (particularly ternatins in flowers), flavonol glycosides, phenolic acids, triterpenoids, sterols and cyclotides. The distribution of these constituents varies with plant part and extraction solvent. Thus, evidence obtained from flower infusions or purified compounds cannot be assumed to describe a methanolic leaf preparation [8].

Prior studies have examined C. ternatea preparations in antioxidant and experimental hepatoprotection models, including acetaminophen- and carbon tetrachloride-associated injury. Recent work has also reported liver-related outcomes in metabolic disease models. Nevertheless, differences in plant part, solvent, toxicant, dose and outcome measures make direct comparison difficult. A further requirement for translational interpretation is explicit characterization of the extract used in each experiment [9-12].

The present study therefore examined the effects of methanolic C. ternatea extract at 200 and 400 mg/kg in male Wistar rats exposed to ethanol, using silymarin as a reference treatment. The primary outcomes were serum SGPT, SGOT, ALP and total bilirubin; qualitative histopathological observations were used as a complementary assessment. The study is presented as an exploratory preclinical evaluation, and conclusions are restricted to the endpoints recorded in the source dataset.

MATERIALS AND METHODS

Plant Material and Extraction

C. ternatea plant material was collected from a localized area of Bhopal, Madhya Pradesh, India. The plant material was cleaned to remove soil and foreign matter, shade-dried, coarsely powdered and stored in an airtight container. Botanical identification was stated to have been confirmed by morphological and taxonomic characteristics. A herbarium voucher number, name of the taxonomist and repository were not provided in the available record and should be added before submission.

The powdered material was extracted using a Soxhlet apparatus with 500 mL methanol. Extraction continued until the solvent in the siphon tube became clear. The extract was filtered and concentrated under reduced pressure using a rotary vacuum evaporator. From 278.89 g of starting plant material, 20.78 g of crude methanolic extract was obtained. Percentage yield was calculated as extract mass divided by starting dry plant mass multiplied by 100, giving 7.45%. The exact extraction temperature, duration, number of extraction cycles and storage temperature were not reported.

Parameter	Reported value
Plant material	Clitoria ternatea (plant material described as leaves in the methods/figure)
Collection location	Bhopal, Madhya Pradesh, India
Extraction method	Soxhlet extraction
Solvent volume	Methanol, 500 mL
Starting dry material	278.89 g
Crude extract mass	20.78 g
Extract yield	7.45%

Acute Oral Toxicity

Acute oral toxicity was assessed using an OECD Guideline 423 acute toxic class approach. The extract was administered orally at sequential dose levels of 5, 50, 300 and 2000 mg/kg body weight. Animals were observed over 14 days for clinical signs, behaviour, locomotor activity, body weight, food intake and mortality. No mortality was reported at any tested dose. Transient eye/nasal signs were recorded at 300 mg/kg, while hair loss, flaky eyes and temporary nasal discharge/bleeding were recorded at 2000 mg/kg. These observations should be reported as recorded rather than interpreted as proof of absence of toxicity. The number of animals used per dose group and the vehicle composition were not clearly specified.

Experimental Animals and Ethical Approval

The hepatoprotective experiment used 30 male Wistar rats weighing approximately 170 ± 20 g. Animals were housed six per cage under reported ambient temperature conditions of 22 ± 2 °C, with standard laboratory feed and water available ad libitum. Animals were acclimatized before experimentation. The protocol approval identifier was PBRI/IAEC/14032026/025.

Experimental design and treatment

Animals were randomly allocated to five groups (six rats per group): Group I, vehicle-treated normal control; Group II, ethanol control receiving ethanol at 1 mL/kg orally; Group III, ethanol plus silymarin at 100 mg/kg orally; Group IV, ethanol plus C. ternatea extract at 200 mg/kg orally; and Group V, ethanol plus C. ternatea extract at 400 mg/kg orally. The treatment period was 14 days. The source table lists ethanol and test/reference treatments over this period but does not provide a sufficiently explicit day-by-day dosing sequence, interval between ethanol and extract, ethanol concentration, or whether administration was concurrent or sequential. These details must be verified and inserted from laboratory records before journal submission.

Group	Treatment	Dose/route	n
I	Vehicle control	Vehicle, oral	6
II	Ethanol control	Ethanol 1 mL/kg, oral	6
III	Reference treatment + ethanol	Silymarin 100 mg/kg, oral; ethanol 1 mL/kg	6
IV	C. ternatea extract + ethanol	Extract 200 mg/kg, oral; ethanol 1 mL/kg	6
V	C. ternatea extract + ethanol	Extract 400 mg/kg, oral; ethanol 1 mL/kg	6

Serum Biochemical Analysis

At the end of the 14-day study, blood was collected from the retro-orbital venous plexus into non-heparinized tubes. Samples were centrifuged at 3000 rpm for 20 min to separate serum. Serum was stored at 4°C pending analysis. SGPT/ALT, SGOT/AST, ALP and total bilirubin were measured using commercial diagnostic reagents and an automated clinical chemistry analyser. The source describes kinetic NADH-based methods for ALT and AST, a p-nitrophenyl phosphate method for ALP, and a diazo-based method for total bilirubin. Manufacturer, kit catalogue numbers, calibration and quality-control data were not supplied.

Histopathological Examination

Liver tissue was collected after the experimental period, washed with ice-cold normal saline and fixed in 10% neutral buffered formalin. Tissues were dehydrated through graded alcohol, cleared with xylene, embedded in paraffin and sectioned at approximately 5 µm. Sections were stained with haematoxylin and eosin and examined by light microscopy. Histopathological observations were descriptive; a blinded scoring system, the number of fields or sections evaluated per animal, magnification and quantitative lesion scores were not reported.

Statistical Analysis

Data are reported as mean ± standard deviation (SD), with n=6 per group. One-way analysis of variance followed by Bonferroni-adjusted pairwise t-tests was used. Overall group differences were reported as $P<0.001$ for each biochemical marker. Exact F statistics and selected pairwise results are reproduced in the Results section. Statistical software/version and checks of normality and homogeneity of variance were not specified. The reported analysis should be independently rechecked against the raw animal-level data before submission; summary statistics alone are insufficient to reproduce the analysis.

RESULTS

Extraction Yield

Soxhlet extraction of 278.89 g of C. ternatea plant material with methanol yielded 20.78 g of crude extract, corresponding to 7.45% w/w. No quantitative phytochemical content, chromatographic fingerprint or marker-compound concentration was provided in the results dataset.

Acute Oral Toxicity Observations

No deaths were recorded during the 14-day observation period at the tested dose levels of 5, 50, 300 and 2000 mg/kg. The 5 and 50 mg/kg groups were described as showing normal clinical observations. Mild transient eye changes and nasal discharge were recorded at 300 mg/kg. At 2000 mg/kg, observations included hair loss, flaky eyes and temporary nasal discharge with occasional bleeding. Body weight and food intake generally increased during the observation period. As the animal numbers per dose group and full individual-level data are not available, these findings are presented descriptively.

Serum SGPT/ALT

Serum SGPT was 41.86 ± 1.31 U/L in the normal control group and 97.54 ± 2.28 U/L in the ethanol control group. Silymarin treatment reduced SGPT to 49.17 ± 1.48 U/L. The extract-treated groups showed values of 68.36 ± 1.76 U/L at 200 mg/kg and 54.73 ± 1.59 U/L at 400 mg/kg. The overall ANOVA was significant ($F(4,25)=980.648$, $P<0.001$). Bonferroni comparisons reported $P<0.001$ for all pairwise comparisons. The 400 mg/kg group therefore showed a lower SGPT value than the 200 mg/kg group, although both remained above the normal control.

Serum SGOT/AST

SGOT increased from 69.84 ± 1.42 U/L in the normal control group to 134.43 ± 2.02 U/L in the ethanol control group. Values were 74.38 ± 1.51 U/L with silymarin, 90.61 ± 1.73 U/L with 200 mg/kg extract and 78.13 ± 1.51 U/L with 400 mg/kg extract. The overall ANOVA was significant ($F(4,25)=1518.880$, $P<0.001$). Bonferroni-adjusted pairwise comparisons were reported as $P<0.001$ except for the 400 mg/kg extract versus silymarin comparison ($P=0.006$), which was also significant at the 0.05 level.

Alkaline Phosphatase

ALP was 118.64 ± 2.14 U/L in the normal control group and 210.64 ± 3.22 U/L in the ethanol control group. Silymarin reduced ALP to 130.53 ± 2.31 U/L. The 200 and 400 mg/kg extract groups showed values of 173.46 ± 2.82 and 137.92 ± 2.54 U/L, respectively. The overall ANOVA was significant ($F(4,25)=1220.786$, $P<0.001$), and all reported Bonferroni pairwise comparisons were $P<0.001$.

Total Bilirubin

Total bilirubin increased from 0.32 ± 0.03 mg/dL in the normal control group to 1.21 ± 0.09 mg/dL in the ethanol control group. Values after treatment were 0.39 ± 0.03 mg/dL for silymarin, 0.55 ± 0.05 mg/dL for 200 mg/kg extract and 0.47 ± 0.04 mg/dL for 400 mg/kg extract. The overall ANOVA was significant ($F(4,25)=274.971$, $P<0.001$). However, the pairwise comparison between the two extract doses was not significant ($P=0.148$), and comparisons of the 400 mg/kg group with silymarin and of silymarin with normal control were also reported as $P=0.148$ and $P=0.306$, respectively. These nonsignificant comparisons should not be described as statistically significant dose separation.

Biochemical marker	Normal control	Ethanol control	Silymarin 100 mg/kg	Extract 200 mg/kg	Extract 400 mg/kg	ANOVA
SGPT (U/L)	41.86 ± 1.31	97.54 ± 2.28	49.17 ± 1.48	68.36 ± 1.76	54.73 ± 1.59	F=980.648; P<0.001
SGOT (U/L)	69.84 ± 1.42	134.43 ± 2.02	74.38 ± 1.51	90.61 ± 1.73	78.13 ± 1.51	F=1518.880; P<0.001
ALP (U/L)	118.64 ± 2.14	210.64 ± 3.22	130.53 ± 2.31	173.46 ± 2.82	137.92 ± 2.54	F=1220.786; P<0.001
Total bilirubin (mg/dL)	0.32 ± 0.03	1.21 ± 0.09	0.39 ± 0.03	0.55 ± 0.05	0.47 ± 0.04	F=274.971; P<0.001

Values are mean ± SD; n=6 per group. ANOVA degrees of freedom: between groups=4, residual=25. Pairwise significance is described in the text; for bilirubin, the 200 versus 400 mg/kg comparison was not significant ($P=0.148$).

Histopathological Observations

The normal control liver was described as having preserved hepatic architecture and a viable periportal region. The ethanol control showed necrosis and disruption of normal architecture. The silymarin group showed binucleated hepatocytes and granular cytoplasm, interpreted in the source as improvement. The 200 mg/kg extract group showed macrophages and inflammatory-cell infiltration, indicating incomplete resolution of injury. The 400 mg/kg group was described as showing sinusoids containing red blood cells and endothelial cells, with better preservation of tissue architecture. These findings are qualitative and should not be interpreted as a quantified reduction in necrosis or proof of hepatocyte regeneration.

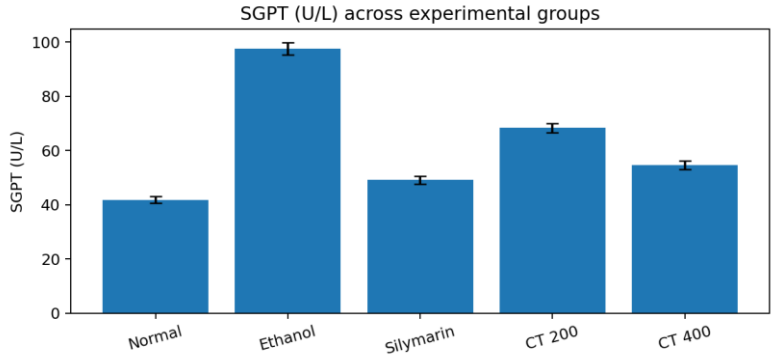

Figure 1. Group-wise serum SGPT (U/L) values (mean ± SD; n=6).

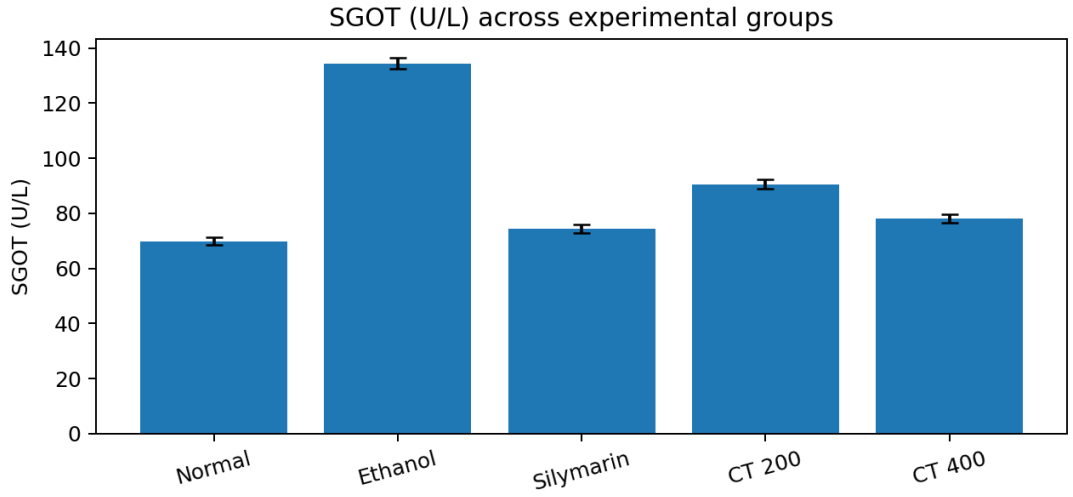

Figure 2. Group-wise serum SGOT (U/L) values (mean ± SD; n=6).

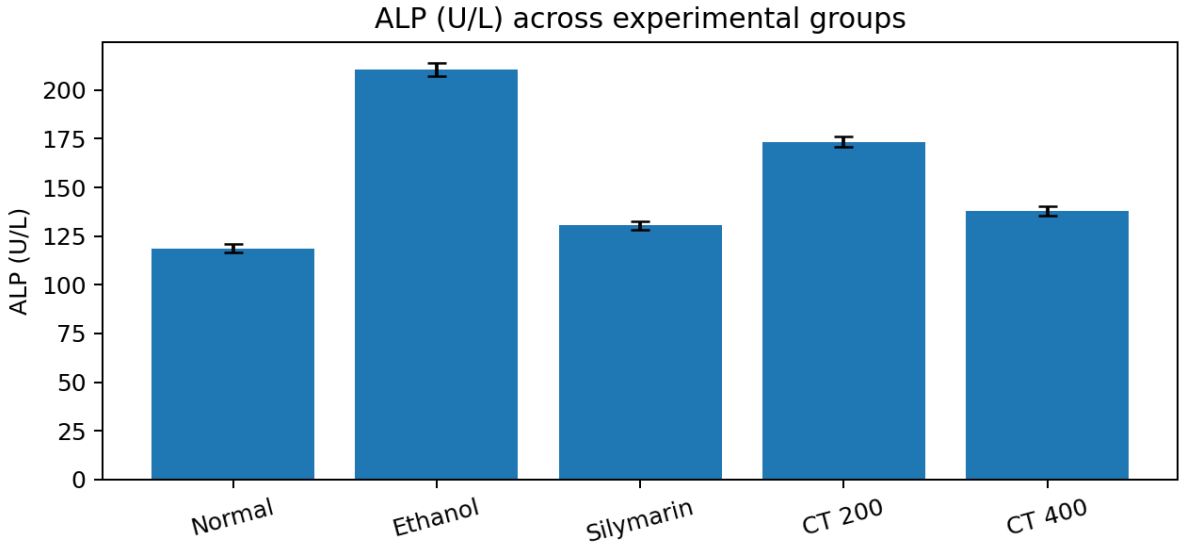

Figure 3. Group-wise serum ALP (U/L) values (mean ± SD; n=6).

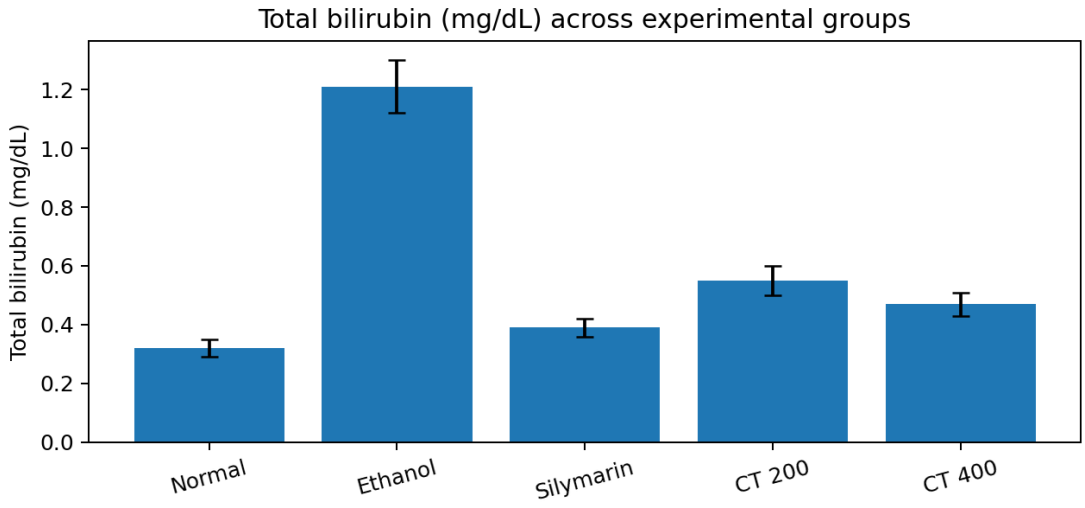

Figure 4. Group-wise serum Total bilirubin (mg/dL) values (mean ± SD; n=6).

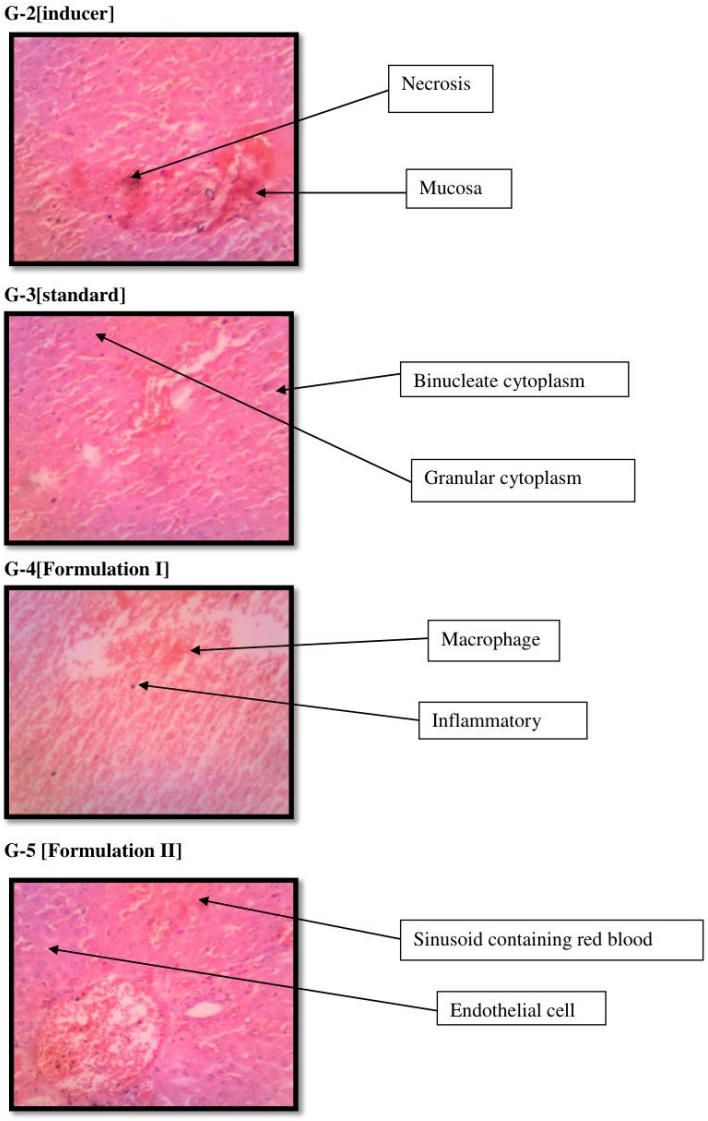

Figure 11: Histopathological studies

Figure 5. Representative liver histopathology images from the experimental groups. The original image annotations should be verified and standardized; the extract groups are identified by dose in the study design.

DISCUSSION

This exploratory study found that ethanol exposure was accompanied by increases in serum SGPT, SGOT, ALP and total bilirubin in male Wistar rats. Administration of methanolic C. ternatea extract at 200 or 400 mg/kg was associated with lower values of each marker relative to the ethanol control. Across the four biochemical endpoints, the 400 mg/kg group showed numerically greater improvement than the 200 mg/kg group. Silymarin produced values closest to the normal control for all four endpoints, indicating that the extract did not match the reference treatment in this experiment.

The pattern of increased aminotransferases is consistent with hepatocellular injury, while the accompanying ALP and bilirubin elevations suggest altered hepatobiliary function or excretory handling. The reduction in these markers in extract-treated groups is compatible with a protective association. Nevertheless, serum enzyme changes are indirect indicators and cannot independently establish the cellular pathway responsible for the observed differences.

C. ternatea is chemically diverse, and the composition of a crude extract depends on plant part, growing conditions, processing and solvent. The source manuscript describes methanolic Soxhlet extraction and a 7.45% yield, but does not provide a phytochemical screening result table, total phenolic/flavonoid measurements or chromatographic characterization. Consequently, any explanation involving flavonoids, phenolics or anthocyanins remains a hypothesis based on literature about the species rather than a demonstrated property of the tested batch. The plant part should also be explicitly confirmed: the plant part is described as leaves in the methods

and figure captions, but a botanical voucher was not provided.

The histopathological descriptions provide qualitative support for the biochemical pattern: ethanol-associated necrosis was reported in the toxicant group, while the higher-dose extract group was described as having better-preserved sinusoids and endothelial structures. However, the histology is not supported by a prespecified scoring system, blinded assessment, multiple representative fields or animal-level lesion data. Terms such as "regeneration" should therefore be used cautiously. The original plate also contains inconsistent labels ("Formulation I" and "Formulation II") even though the study evaluates crude extract doses; these labels must be corrected after confirmation of the images.

Several design and reporting limitations restrict the strength of inference. First, the ethanol concentration and exact dosing sequence are not specified, and the methods do not clearly establish whether the extract was administered before, with or after ethanol. Second, randomization is mentioned but the method of sequence generation and allocation concealment are not described; blinding of biochemical analysts and histopathologists is not reported. Third, the sample size is six animals per group and no prospective sample-size calculation is available. Fourth, only four serum biochemical markers and descriptive histology are reported. Liver oxidative stress markers (for example, GSH, MDA, SOD and catalase), inflammatory mediators, CYP2E1 expression, liver weight, histological scoring and extract pharmacokinetics were not measured or reported. Fifth, the acute toxicity section does not specify the number of animals per dose or provide a complete individual-level dataset.

The statistical appendix reports highly significant overall ANOVA results for all markers. The pairwise comparisons should nevertheless be presented accurately: the bilirubin difference between the two extract doses was not significant (P=0.148), and the 400 mg/kg versus silymarin comparison was also not significant (P=0.148). The paper should not claim that every dose-to-dose comparison was statistically significant. In addition, the original results section includes significance stars that are not consistently aligned with the statistical appendix; the raw data and analysis output should be reconciled before submission.

Future investigations should use a voucher-authenticated plant source, a reproducible extraction protocol and chemical fingerprinting (e.g., HPLC or LC-MS) with defined marker compounds. A clearly specified ethanol regimen, randomized allocation, blinded endpoint assessment, prospective power calculation and reporting aligned with ARRIVE 2.0 would improve reproducibility. Mechanistic studies should include oxidative stress, inflammatory and mitochondrial endpoints, together with a validated quantitative histopathology score. These studies are necessary before the preparation can be considered a standardized hepatoprotective candidate.

CONCLUSION

In this 14-day rat experiment, methanolic C. ternatea extract at 200 and 400 mg/kg was associated with lower serum SGPT, SGOT, ALP and total bilirubin values than ethanol alone, accompanied by qualitative descriptions of improved liver histology. The 400 mg/kg dose showed greater numerical improvement than 200 mg/kg across the reported markers, although the difference between these doses was not statistically significant for total bilirubin. Silymarin showed the strongest overall biochemical normalization. The findings support further investigation, but do not establish a mechanism, clinical efficacy or a standardized therapeutic product.

REFERENCES

1. Jeyaraj EJ, Lim YY, Choo WS. Extraction methods of butterfly pea (Clitoria ternatea) flower and biological activities of its phytochemicals. Journal of Food Science and Technology. 2021;58:2054–2067. https://doi.org/10.1007/s13197-020-04745-3.
2. Oguis GK, Gilding EK, Jackson MA, Craik DJ. Butterfly pea (Clitoria ternatea), a cyclotide-bearing plant with applications in agriculture and medicine. Frontiers in Plant Science. 2019;10:645. https://doi.org/10.3389/fpls.2019.00645.
3. Mukherjee PK, Kumar V, Kumar NS, Heinrich M. The Ayurvedic medicine Clitoria ternatea-from traditional use to scientific assessment. Journal of Ethnopharmacology. 2008;120(3):291–301. https://doi.org/10.1016/j.jep.2008.09.009.
4. Nithianantham K, Ping KY, Latha LY, Jothy SL, Darah I, Chen Y, Chew A-L, Sasidharan S. Evaluation of hepatoprotective effect of methanolic extract of Clitoria ternatea (Linn.) flower against acetaminophen-induced liver damage. Asian Pacific Journal of Tropical Disease. 2013;3(4):314–319. https://doi.org/10.1016/S2222-1808(13)60075-4.
5. Shanmugasundaram R, Devi VK, Tresina PS, Maruthupandian A, Mohan VR. Hepatoprotective activity of ethanol

extracts of Clitoria ternatea L. and Cassia angustifolia Vahl leaf against CCl4-induced liver toxicity in rats. International Research Journal of Pharmacy. 2010;1(12):237–241.

6. Atanasov AG, Zotchev SB, Dirsch VM, Supuran CT. Natural products in drug discovery: advances and opportunities. Nature Reviews Drug Discovery. 2021;20:200–216. https://doi.org/10.1038/s41573-020-00114-z.
7. Zakhari S, Neuman M, Seitz HK. The role of cytochrome P4502E1 in ethanol mediated diseases: a narrative update. Alcohol and Alcoholism. 2025;60(3):agaf014. https://doi.org/10.1093/alcalc/agaf014.
8. Nagarjuna D, Karthikeyan E. Alcohol-associated liver disease: A review. Gastroenterology & Endoscopy. 2025;3(2):65–85. https://doi.org/10.1016/j.gande.2025.01.003.
9. Devi DR, Maheswari SN, Saranya RK, et al. Clitoria ternatea as a phytopharmacological resource: plant metabolites, mechanistic evidence, translational prospects, and safety considerations. Frontiers in Pharmacology. 2026;17:1922024. https://doi.org/10.3389/fphar.2026.1922024.
10. Widowati W, Darsono L, Utomo HS, et al. Antidiabetic and hepatoprotection effect of butterfly pea flower (Clitoria ternatea L.) through antioxidant, anti-inflammatory, lower LDH, ACP, AST, and ALT on diabetes mellitus and dyslipidemia rat. Heliyon. 2024;10(8):e29812. https://doi.org/10.1016/j.heliyon.2024.e29812.
11. Organisation for Economic Co-operation and Development (OECD). Test No. 423: Acute Oral Toxicity-Acute Toxic Class Method. OECD Guidelines for the Testing of Chemicals, Section 4. OECD Publishing, Paris. https://doi.org/10.1787/9789264071001-en.
12. Percie du Sert N, Hurst V, Ahluwalia A, et al. The ARRIVE guidelines 2.0: updated guidelines for reporting animal research. PLOS Biology. 2020;18(7):e3000410. https://doi.org/10.1371/journal.pbio.3000410.