

Research Article

# Klebsiella pneumoniae Isolated from Splenic abscess of a patient with autoimmune haemolytic anaemia: A Case Report

Priya Dharsini S<sup>1</sup>, Dr. Nishanthi.M<sup>2</sup>, Dr. R. Vasanthi<sup>3</sup>

<sup>1</sup>Tutor, Department of Microbiology, Madha Medical college.

<sup>2</sup>Assistant professor, Madha Medical College.

<sup>3</sup>Professor & Head of the Department, Madha Medical College

Received: 08.03.25, Revised: 01.05.25, Accepted: 27.05.25

## ABSTRACT

Splenic abscesses may be solitary or multiple and are unusual infections. Signs and symptoms are variable and do not always include left upper quadrant pain or tenderness, as the Case Report illustrate. Abscesses of the spleen may occur because of endocarditis or from hematogenous seeding from a distant focus of infection. Computed tomographic scan of the spleen is the diagnostic method of choice. We report a case of Splenic abscess caused by *Klebsiella pneumoniae* from a Patient who was diagnosed with splenic abscess and underwent splenectomy for the same.

**Keywords:** Splenectomy, Autoimmune hemolytic anemia, *Klebsiella pneumoniae*, Splenic abscess, Anemia.

## INTRODUCTION

Autoimmune haemolytic anaemia (AIHA) is characterized by the increased destruction of autologous red blood cells (RBCs) due to the presence of immunoglobulin (Ig)G, IgM, IgA, or complements (usually C3d) bound to RBC membrane antigens. The patient with the underlying autoimmune disease presents with shortened RBC survival due to haemolysis. Weakness, dyspnoea, jaundice, acrocyanosis or Raynaud phenomena, and splenomegaly are common symptoms [1]. Three Major pathophysiologic mechanisms for development of splenic abscess which usually results from bacteraemia, hematogenous spread and septic emboli to the spleen typically from bacterial endocarditis or another endovascular infection (infected pacemaker wire, mycotic aneurysm). The second mechanism is again related to bacteraemia and hematogenous spread from a pyogenic infection but this time in the setting of disrupted splenic architecture, for example due to trauma or splenic infarcts (hemoglobinopathies, vasculitis). The third mechanism refers to contiguous spread via fistula formation complicating an infection, trauma, perforation, or malignancy of an adjacent organ (stomach, pancreas, colon) [2] The diagnosis of a splenic abscess is a clinical challenge. The usual symptoms include triad of fever, left upper quadrant tenderness, and leucocytosis, which is mostly present in one-third of the patients. [3]

## Case Report

A 69-year-old women was admitted to surgical ward on September 3<sup>rd</sup> 2023 with complaints of fever along with giddiness and easy fatigability, decreased speech since two days. Patient is known hypertensive since 10 years on treatment with Tab Telmivas 20 mg/day. On clinical examination patient was conscious, oriented, obeying to commands, pale, icteric, vitals are stable, CVS-s1& s2 present, RS-B/L air entry present, but reduced breath sounds on left basal side of chest, spleen was palpable. On laboratory examination CBC with peripheral smear showed macrocytic anemia, neutrophilic leucocytosis with haemoglobin of 4.1mg/dl on September 3<sup>rd</sup> 2023. She was diagnosed with severe anaemia for which patient was given 8 units of blood transfusion and direct coombs test was done on September 8<sup>th</sup> 2023, which turned to be positive, indirect coombs test was negative which implied patient was suffering from autoimmune haemolytic anaemia. USG abdomen showed well defined heterogeneous hypoechoic lesion in upper pole of spleen with no internal vascularity, low level internal echoes which indicated evolving abscess or mass. USG splenoportal doppler confirmed the presence of evolving splenic abscess. Carotid vertebral doppler is normal. CT Abdomen showed pelvis with contrast revealing splenic abscess in upper pole of spleen measuring 7.2x6.3 cm. Whole body PET-CT also revealed features suggestive of

splenic abscess. Hence patient was taken by surgical gastroenterology team for laparoscopy and open splenectomy. Patient underwent splenectomy on September 29<sup>th</sup> 2023, abscess was aspirated and sent to microbiology lab for culture and sensitivity.

Pus sent to lab from the splenic abscess was greyish green in colour and the direct gram staining of the sample showed plenty of RBCs with moderate pus and gram-negative bacilli. After 24 hours of streaking, blood agar and chocolate agar plate revealed grey mucoid colonies and Mac Conkey agar revealed pink lactose fermenting mucoid colonies. The Gram staining from colonies of all three plates revealed Gram negative bacilli. For further confirmation of organism identification, biochemical tests were done, which inferred

indole as negative, citrate and urease positive, triple sugar iron showed acid butt /acid slant with abundant gas. Mannitol motility test confirmed organism to be a fermentative, non-motile & gram negative bacilli.

Antibiotic sensitivity was done on Mueller Hinton Agar plate by Kirby Bauer disc diffusion method which showed susceptibility to all antibiotics. It was sensitive to antibiotics like cefazolin, cefuroxime, cotrimoxazole, gentamycin, ciprofloxacin, cefepime, piperacillin tazobactam, meropenem, imipenem, aztreonam and intrinsically resistant to antibiotic like Ampicillin. The strain was neither AMPC  $\beta$  lactamase resistant according to Varsha et al [6] nor multi drug resistant organism.

Figure A

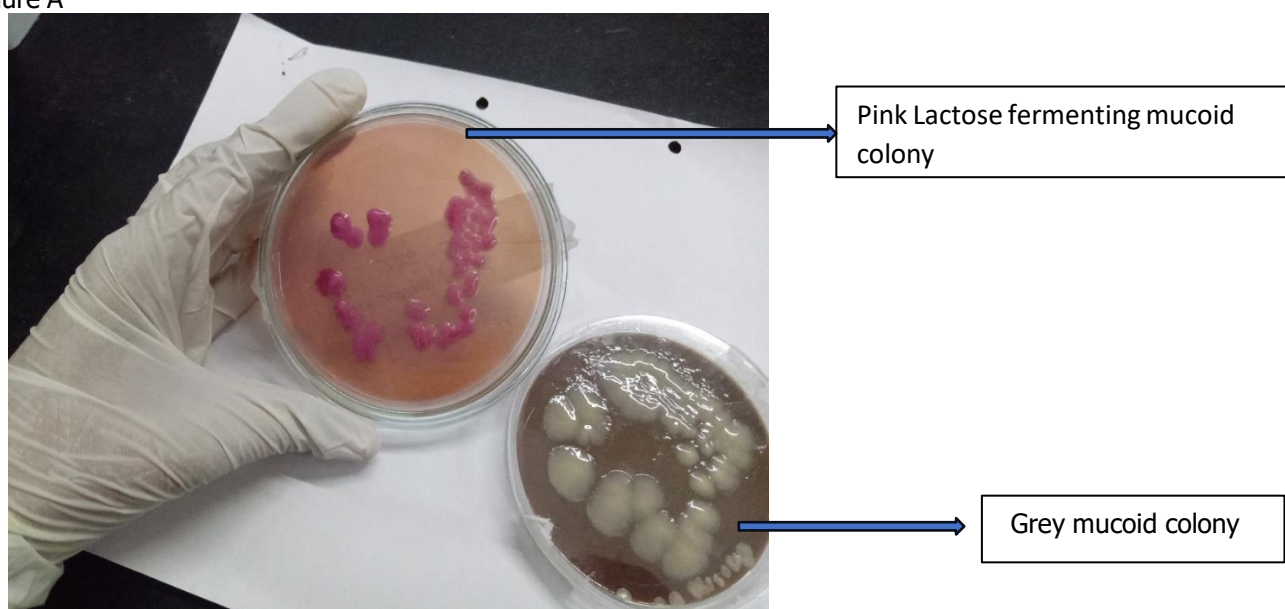


Figure A showing Mac Conkey agar plate with lactose fermenting mucoid colonies and chocolate agar showing grey mucoid colonies

Figure B




Figure B showing biochemical test-Indole (-), citrate (+), urease (+), TSI (Acid/Acid with gas ++), Mannitol Motility Medium (Fermented/Non-Motile)




Figure C-Antimicrobialsusceptibility testing

Central line tip for culture was also sent for the same patient revealing same organism but Antimicrobial sensitivity test by Kirby bauer disc diffusion method revealed multidrug resistant organism with resistance to ampicillin, tetracycline, cefazolin, cefuroxime, imipenem, sensitive to aminoglycosides, ciprofloxacin, cotrimoxazole, cefepime, aztreonam, piperacillin-tazobactam and meropenem. Since the patient had sepsis, broad spectrum antibiotics like Inj.Piptaz for a 7 day course was being administered to the patient. Post-operative period was uneventful for the patient and suture removal done on 9/10/2023. Discharge was planned on 5/10/2023 with advice on wound care also the patient was advised to take pneumococcal vaccine and H1N1 Influenza vaccine. This could be a *Klebsiella pneumoniae* invasive syndrome as stated by Vasco et al [7]. Thus, the patient was treated with amikacin (IV) & meropenem (IV).

Other investigations like D-Dimer -6780ng/ml, CRP-131 mg/dl were elevated. Urine routine examination was normal, urine culture and sensitivity done on 28/9/2023 showed significant growth of *Candida non-albicans*. Blood culture on 28/9/2023 showed no growth, Post splenectomy abscess aspirate was sent for fungal KOH mount and culture sensitivity on 23.9.2023 which showed no fungal elements and no fungal growth. Since patient had giddiness neurologists opinion was asked they suggested CT brain where no significant abnormality detected. MRI brain showed multiple parietal acute infarcts in bilateral fronto temporal region with no midline shift, no mass effect. Neurologists diagnosed patient to have hypotensive brain injury. Stool occult blood test was negative and liver function test showed mild elevated total and direct bilirubin levels, renal function test normal. In view of decreased breath sounds, patient's sputum was sent for acid fast bacilli and Gene expert for *Mycobacterium*

tuberculosis was negative. CT chest plain was done which suggested bilateral mild pleural effusion with passive atelectasis of both lower lobes of lungs. Air space opacification with consolidation in right upper lobe and posterior segments of both lower lobes suggestive of infectious etiology.

Even though *K. pneumoniae* is a normal flora of the human oral cavity and intestine, it is well-known to cause nosocomial and community-acquired infections resulting in pneumonia or urinary tract infections [4]. Most of the articles revealed the presence of *Klebsiella pneumoniae* in liver abscess[8]. There are just a few numbers of articles indicating the reason for splenic abscess to be *Klebsiella pneumoniae*. According to Maria et al, *Klebsiella pneumoniae* also have the ability to produce biofilms [5].

## DISCUSSION

Pyogenic splenic abscess is uncommon and remains a diagnostic challenge to clinicians. Common predisposing causes of splenic abscess include concurrent pyogenic infection at distant site, splenic trauma, hemoglobinopathies, and existing infection adjacent to the spleen. Hematogenous spread is the most common cause of splenic abscess. It typically results from endocarditis or seeding from some contiguous sites of infection. Other risk groups include immunosuppressed patients, hemoglobinopathies, and diabetes mellitus. In a study done by Thambu et al a splenic aspirate done revealed numerous gram-negative bacilli that were later found to be ESBL *Klebsiella pneumoniae*. It was resistant to ampicillin, ceftazidime, cefotaxime, cephalexin, ofloxacin, ciprofloxacin, amikacin, gentamicin, ceftiofame, piperacillin, azlocillin and aztreonam. It was sensitive to imipenem, meropenem and isepamicin. He was started on IV meropenem 1g twice daily [9]. In another study done by Won suk lee et al revealed that the higher percentage of *K. pneumoniae* in our study is most likely due to a sequela of metastatic infection from the liver to the spleen, or a coinfection of both. These results indicate the significance of the role of gram-negative bacterial infection in splenic abscesses [10].

In a similar study carried by Hung et al, presented the first case with abscesses caused by community-acquired *K. pneumoniae* in the kidneys and spleen without liver invasion. In conclusion, this case report alerts clinicians to

the possibility that *K. pneumoniae* bacteremia combined with multiple abscesses can be associated with severe NSAID-induced colitis. [11]

## CONCLUSION

We present a case of spontaneous splenic abscess in a hypertensive patient with other predisposing factors like Autoimmune hemolytic anemia. Although the causative agent was identified, the patient was initially treated with empiric antibiotic therapy and later targeted therapy after isolating *Klebsiella pneumoniae* from splenic abscess and surgical treatment like Laparoscopic and open splenectomy was done and post operative period was uneventful patient haemoglobin status improved and finally patient was discharged. Splenic abscess is a life-threatening condition hence prompt diagnosis and early initiation of appropriate treatment are key to the successful management of this disease.

## REFERENCE

1. Cvetković Z, Pantić N, Cvetković M, et al. The Role of the Spleen and the Place of Splenectomy in Autoimmune Hemolytic Anemia-A Review of Current Knowledge. *Diagnostics* (Basel). 2023;13(18):2891. Published 2023 Sep 9. doi:10.3390/diagnostics13182891.
2. Nikolaidis N, Giouleme O, Gkissakis D, Grammatikos N. Posttraumatic splenic abscess with gastrosplenic fistula. *Gastrointest Endosc* 2005 May;61(6):771- [CrossRef] [PubMed]
3. Lotfollahzadeh S, Mathew G, Zemaitis MR. Splenic Abscess. [Updated 2023 Jun 3]. In: StatPearls [Internet]. Treasure Island (FL): StatPearls Publishing; 2024 Jan
4. Zeng S, Yan WQ, Wu XM, Zhang HN. Case Report: Diagnosis of *Klebsiella pneumoniae* Invasive Liver Abscess Syndrome With Purulent Meningitis in a Patient From Pathogen to Lesions. *Front Med* (Lausanne). 2021;8:714916. Published 2021 Sep 10. doi:10.3389/fmed.2021.714916.
5. Guerra MES, Destro G, Vieira B, et al. *Klebsiella pneumoniae* Biofilms and Their Role in Disease Pathogenesis. *Front Cell Infect Microbiol*. 2022;12:877995. Published 2022 May 11. doi:10.3389/fcimb.2022.877995

6. Gupta V, Kumarasamy K, Gulati N, Garg R, Krishnan P, Chander J. AmpC  $\beta$ -lactamases in nosocomial isolates of *Klebsiella pneumoniae* from India. *Indian J Med Res.* 2012;136(2):237-241.
7. Evangelista V, Gonçalves CV, Almeida R, et al. *Klebsiella pneumoniae* Invasive Syndrome. *Eur J Case Rep Intern Med.* 2018;5(3):000800. Published 2018 Mar 21. doi:10.12890/2018\_000800
8. Lee CH, Hu TH, Liu JW. Splenic abscess caused by *Klebsiella pneumoniae* and non-*Klebsiella pneumoniae* in Taiwan: emphasizing risk factors for acquisition of *Klebsiella pneumoniae* splenic abscess. *Scand J Infect Dis.* 2005;37(11-12):905-909. doi:10.1080/00365540500333624.
9. Thambu D, Pichamuthu K, Varghese GM, Subramanian S. Community-acquired, fatal extended spectrum beta lactamase producing *Klebsiella pneumoniae* splenic abscess and sepsis. *J Postgrad Med.* 2006 Oct-Dec;52(4):328-9.
10. Lee WS, Choi ST, Kim KK. Splenic abscess: a single institution study and review of the literature. *Yonsei Med J.* 2011 Mar;52(2):288-92.
11. Huang, HL., Lu, PL., Lin, CY. et al. *Klebsiella pneumoniae* bacteremia and renosplenic abscesses without intestinal symptoms as the initial manifestations of non-steroidal anti-inflammatory drug-induced colitis: a rare case report. *BMC Gastroenterol* 13, 139 (2013). <https://doi.org/10.1186/1471-230X-13-139>.