

Research Article

# Clinicopathological Profile and Hormone-Receptor Status of Malignant Surface Epithelial Tumours of the Ovary: A Prospective-Retrospective Study from A Tertiary Military Centre

Dr Nalin Shankar Singh<sup>1\*</sup>, Dr M K Patra<sup>2</sup>, Dr Amarinder Singh<sup>3</sup>

<sup>1\*</sup>Dept of Pathology Command Hospital Udhampur.

<sup>2</sup>Dept of Pathology Command Hospital Udhampur

<sup>3</sup>Dept of OBG Command Hospital Udhampur

Received: 12.05.25, Revised: 14.06.25, Accepted: 16.07.25

## ABSTRACT

**Background.** Surface-epithelial tumours account for ~90% of malignant ovarian neoplasms, yet data on the expression of oestrogen receptor (ER), progesterone receptor (PR) and human epidermal growth factor receptor-2 (HER2-neu) in Indian patients remain limited. This study characterises the clinicopathological spectrum of malignant surface-epithelial ovarian tumours and evaluates ER, PR and HER2-neu expression in relation to established prognostic markers.

**Methods.** After institutional-ethics approval, a combined prospective-retrospective observational study was performed in the Department of Pathology, Command Hospital (Northern Command). Fifty consecutive patients operated for ovarian tumours between May 2024 and May 2025 were screened; four were excluded because of scant tumour in deeper sections, yielding 46 analysable cases. Detailed clinical data were retrieved, tumours were classified per WHO 2020 and FIGO 2021 criteria, and immunohistochemistry for ER, PR (nuclear) and HER2-neu (membranous) was performed and scored independently by two pathologists. Associations were tested with  $\chi^2$ / Fisher's exact test, t-test or one-way ANOVA;  $p < 0.05$  was considered significant.

**Results.** Median age was 52 years (range 26-74). High-grade serous carcinoma predominated (71.7%), followed by mucinous carcinoma (17.4%). ER and PR positivity were seen in 65.2% and 58.7% respectively, while HER2-neu over-expression (3+) occurred in 30.4%. ER and PR correlated strongly with tumour grade (high > low;  $p < 0.001$  each) but not with age or FIGO stage. HER2-neu positivity was significantly enriched in high-grade tumours ( $p = 0.001$ ) and in mucinous histology (50%,  $p = 0.92$ ). Triple-positive phenotype (ER+ PR+ HER2+) comprised 10.9% of cases—exclusively high-grade—whereas triple-negative tumours constituted 26.1%. No significant correlation was found between receptor status and pre-operative CA-125 levels.

**Conclusion.** ER and PR are expressed in nearly two-thirds of malignant surface-epithelial ovarian tumours, especially high-grade lesions, underscoring the potential utility of endocrine therapy. HER2-neu over-expression, although less common, clusters within high-grade and mucinous carcinomas and may identify candidates for anti-HER2 therapy. Routine assessment of these biomarkers could refine risk-stratification and open avenues for targeted treatment in Indian ovarian-cancer patients.

**Keywords:** ovarian carcinoma; surface-epithelial tumours; oestrogen receptor; progesterone receptor; HER2-neu; immunohistochemistry; India

## INTRODUCTION

Epithelial ovarian cancer (EOC) is the deadliest gynaecological malignancy, responsible for an estimated 313959 new cases and 207252 deaths worldwide in 2022 [1]. Late presentation, biological heterogeneity and the absence of effective screening contribute to a 5-year survival of <45% [2]. Histologically, ~90% of EOCs arise from the ovarian surface epithelium and are broadly categorised into serous, mucinous, endometrioid, clear-cell,

transitional (Brenner) and undifferentiated types [3]. Contemporary dualistic models distinguish low-grade, indolent Type I tumours from aggressive, genomically unstable Type II tumours, predominantly high-grade serous carcinoma (HGSC) [4].

While cytoreductive surgery followed by platinum-taxane chemotherapy remains the therapeutic backbone, interest in targeted and hormonal therapies for selected subsets is resurging [5]. ER and PR are established

predictive markers in breast and endometrial carcinoma; their expression in EOC varies widely (ER: 16–86%, PR: 9–63%) across series, partly reflecting histotype and scoring heterogeneity [6,7]. Meta-analyses suggest that PR positivity confers a survival advantage, whereas ER status shows inconsistent prognostic value [8]. Likewise, HER2-neu over-expression/amplification is reported in 6–35% of EOCs, with enrichment in mucinous tumours and controversial prognostic implications [9]. Trastuzumab and other HER2-targeted agents demonstrate modest activity in HER2-positive EOC, highlighting the need to refine patient selection [10].

Indian data remain sparse, especially from military and northern populations, where unique demographic and environmental factors may influence tumour biology. Moreover, information on the combined 'triple-marker' (ER/PR/HER2) landscape—crucial for stratifying endocrine versus anti-HER2 strategies—is limited. Against this backdrop, the present study was designed with three objectives: (i) to delineate the clinicopathological profile of malignant surface-epithelial ovarian tumours treated at a tertiary military hospital; (ii) to evaluate ER, PR and HER2-neu expression patterns; and (iii) to correlate biomarker status with common prognostic parameters, including age, histological subtype, grade, stage and CA-125 levels.

By integrating prospective specimens with well-annotated retrospective cases, we provide a contemporary snapshot of ovarian-cancer biology in an Indian cohort and discuss therapeutic implications in the era of precision oncology.

## MATERIALS AND METHODS

**Study Design and Setting:** This observational study combined a prospective arm (fresh surgical specimens) with a retrospective arm (archival blocks + records) at the Department of Pathology, Command Hospital (Northern Command), Udhampur. Ethical approval No. CHNC/IEC/24-05 was obtained.

**Patient Selection:** All consecutive women undergoing surgery for ovarian mass (May 2024–May 2025) and histologically proven malignant surface-epithelial tumours were eligible. Exclusion criteria: inadequate tissue for immunohistochemistry (IHC) or non-epithelial histology. Of 50 screened patients, 4 were excluded, leaving 46 cases.

**Clinical And Pathological Data:** Demographics, presenting symptoms, imaging, FIGO stage (2021), surgical details and follow-up were extracted from electronic records. Tumours were classified per WHO 2020; grading followed the MD Anderson two-tier system.

**Tissue Handling and IHC:** Prospectively, specimens were fixed in 10% neutral-buffered formalin (12–18 h), grossed systematically and sampled. Retrospective blocks were re-evaluated. Four-micron paraffin sections were stained with H&E; representative blocks underwent IHC on poly-L-lysine slides using the PAP method (Biogenex). Antibodies: ER (clone SP1, ready-to-use), PR (clone PgR 636) and HER2/neu (clone CB11, 1:200). Antigen retrieval employed Tris-EDTA, pH 9, microwave 3 × 8 min at 99 °C. Positive controls: breast carcinoma (ER/PR) and known HER2-positive breast cancer; negative control omitted primary antibody.

### Scoring:

ER/PR: the Allred system (proportion 0–5 + intensity 0–3; total 0–8). Scores ≥ 3 were considered positive.

HER2-neu: ASCO/CAP 2023 criteria for gastric/ovarian tumours—0/1+ = negative, 2+ = equivocal (reflex FISH not feasible), 3+ = positive.

**Statistical Analysis:** Data were entered in Microsoft Excel and analysed with SPSS v16. Continuous variables are mean ± SD; categorical variables as frequencies (%). Associations between categorical variables used  $\chi^2$  or Fisher's exact; between categorical and continuous variables, t-test or one-way ANOVA.  $p < 0.05$  denoted significance.

## RESULTS

Among 46 patients analysed, abdominal pain (32.6%) and distension (28.2%) were leading presentations (Table 1). Mean tumour size was  $9.6 \pm 3.2$  cm; 58.7% were FIGO stage III/IV at diagnosis.

Histopathology revealed 33 serous, eight mucinous, one Brenner, one endometrioid, two undifferentiated and one mixed carcinoma (Figure 1). High-grade morphology dominated (67.4%). Mean pre-operative CA-125 was  $564 \pm 213$  U mL<sup>-1</sup>, highest in mixed tumours (720 U mL<sup>-1</sup>) but without significant inter-histotype differences ( $p = 0.45$ ).

**Hormone-receptor profile:** ER positivity (Allred  $\geq 3$ ) occurred in 30/46 (65.2%) and PR positivity in 27/46 (58.7%). HER2-neu was positive (3+) in 14 cases (30.4%) and equivocal (2+) in six (13%) (Figure 2).  
Correlations.

**Grade:** ER and PR positivity were significantly higher in high-grade tumours (53.3% and 80% respectively) versus low-grade (0% and 18.8%;  $p < 0.001$ ). HER2-neu positivity likewise enriched in high-grade (14.3% vs 6.3%;  $p = 0.001$ ).

**Histotype:** Mucinous carcinomas showed the greatest HER2-neu positivity (50%), whereas serous tumours showed the highest combined ER/PR positivity, but inter-histotype differences were not statistically significant.

**Stage:** No receptor significantly correlated with FIGO stage or CA-125.

Triple-positive phenotype was confined to high-grade tumours (5/46, 10.9%); triple-negative phenotype (ER- PR- HER2-) comprised 12 cases (26.1%), mostly serous.

Table 1. Clinical Presentation of Malignant Surface-Epithelial Ovarian Tumours (N = 46)

Symptom	n	%
Abdominal pain	15	32.6
Abdominal distension	13	28.2
Lower abdominal discomfort	9	19.6
Vaginal bleeding	3	6.5
Dyspepsia	4	8.6
Urinary symptoms	2	4.3

Table 2. Distribution of Histological Subtypes and Grades

Histology	n (%)	Low-grade	High-grade
Serous	33 (71.7)	8	25
Mucinous	8 (17.4)	5	3
Brenner	1 (2.2)	1	0
Endometrioid	1 (2.2)	0	1
Undifferentiated	2 (4.3)	0	2
Mixed	1 (2.2)	0	1

Table 3. Correlation of Hormone-Receptor Status with Tumour Grade

Grade	ER+	PR+	HER2+
Low (n = 16)	0 (0%)	3 (18.8%)	1 (6.3%)
High (n = 30)	16 (53.3%)	24 (80.0%)	13 (43.3%)
<i>p</i> -value	< 0.001	< 0.001	0.001

Table 4. Triple-Marker Phenotypes

Phenotype	n	%
ER+ PR+ HER2+ (Triple-positive)	5	10.9
ER+ PR+ HER2-	6	13.0
ER/PR- HER2+	6	13.0
ER- PR- HER2- (Triple-negative)	12	26.1
Others (mixed)	17	37.0

Figure 1. Distribution of malignant ovarian surface epithelial tumour subtypes

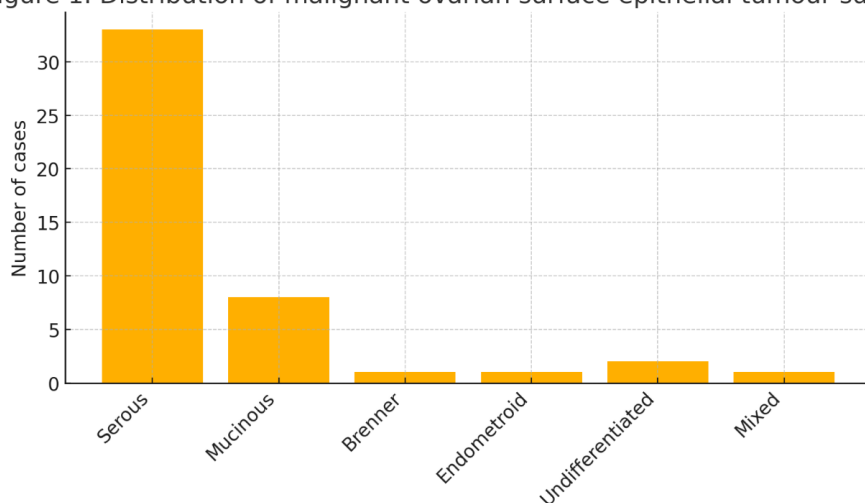


Figure 1. Histogram showing the distribution of malignant ovarian surface-epithelial tumour subtypes (serous predominates, 71.7 %).

Figure 2. Prevalence of ER, PR and HER2-neu positivity in low- vs high-grade tumours

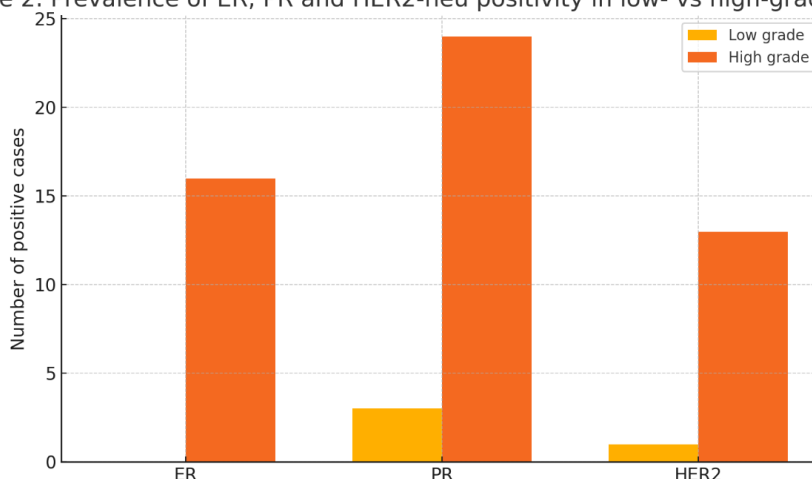


Figure 2. Bar Chart Depicting the Prevalence of ER, PR and HER2-Neu Positivity across High- versus Low-Grade Tumours.

## DISCUSSION

This single-centre study provides contemporary data on hormone-receptor expression in malignant surface-epithelial ovarian tumours from northern India. The histotype distribution mirrors global patterns, with HGSC forming the majority [3, 4]. Median age (52 years) aligns with Indian registry data, which report a slightly younger onset than Western cohorts [11].

**Hormone Receptors:** ER positivity (65.2 %) in our series sits within the heterogeneous range reported (45–80 %) [6, 12], whereas PR positivity (58.7 %) is toward the higher end, possibly reflecting methodological differences (Allred scoring) or population biology. Crucially, both ER and PR were significantly associated

with high-grade morphology, contrasting with studies that link PR to favourable prognosis [8, 13]. This discrepancy may stem from our small low-grade subset (n = 16) and warrants larger validation. Nonetheless, endocrine therapy—including tamoxifen, aromatase inhibitors and selective ER degraders—has shown modest but durable responses in ER/PR-positive relapsed EOC [14]. Our data support routine receptor testing to guide such interventions, particularly when chemotherapy options are exhausted.

**HER2-neu:** HER2-neu over-expression (30.4 %) exceeded many Western series (6–20 %) but parallels Asian studies [15]. Consistent with prior work, mucinous

carcinomas displayed the highest HER2-positive rate (50%) [9,16], underscoring the rationale for considering HER2-targeted agents. The association of HER2 positivity with high-grade tumours corroborates meta-analytic evidence linking HER2 to aggressive behaviour and inferior survival [17].

**Triple-Marker Phenotypes:** The triple-positive cluster (10.9%) identified here is of particular therapeutic interest: trastuzumab-deruxtecan has demonstrated impressive activity in HER2-expressing solid tumours, with enhanced response in hormone-receptor-positive subsets [18]. Conversely, triple-negative tumours (26.1%) may benefit from immune-checkpoint inhibitors or PARP inhibitors when BRCA-mutated [19].

**Clinical Correlations:** We found no significant correlation between receptor status and FIGO stage or CA-125 levels, echoing prior reports [12,15]. Biomarkers thus appear to reflect tumour biology rather than metastatic burden, reinforcing their independent prognostic/therapeutic value.

**Strengths and Limitations:** Strengths include prospective tissue handling with uniform IHC protocols and blinded scoring. Limitations comprise single-centre design, modest sample size—particularly of non-serous subtypes—and lack of survival analysis or HER2 FISH confirmation for 2+ cases. Future multicentric studies with molecular sub-typing (p53, BRCA, HRD status) could refine biomarker-driven algorithms.

In summary, our findings support integrated ER/PR/HER2 testing in ovarian cancer care pathways and highlight a subset of Indian patients who could benefit from endocrine or anti-HER2 strategies, aligning with precision-oncology goals.

## CONCLUSION

Malignant surface-epithelial ovarian tumours in our cohort were predominantly high-grade serous carcinomas presenting at advanced stage. ER and PR positivity occurred in roughly two-thirds of cases, while HER2-over-expression was observed in nearly one-third—particularly in high-grade and mucinous carcinomas. Triple-positive and triple-negative phenotypes comprised 10.9% and 26.1% respectively. These data emphasise the biological heterogeneity of ovarian cancer and support routine hormone-receptor and

HER2 evaluation to refine prognostication and expand therapeutic options through endocrine or HER2-targeted agents in appropriately selected Indian patients.

## REFERENCES

1. Sung H., Bray F., Laversanne M., Ferlay J., Siegel R. L., Soerjomataram I., & Jemal A. (2024). Global cancer statistics 2022: GLOBOCAN estimates of incidence and mortality worldwide for 36 cancers in 185 countries. *CA: A Cancer Journal for Clinicians*, 74(3), 229-263. <https://doi.org/10.3322/caac.21834>
2. Siegel R. L., Giaquinto A. N., & Jemal A. (2024). *Cancer statistics, 2024*. *CA: A Cancer Journal for Clinicians*, 74(1), 12-49. <https://doi.org/10.3322/caac.21820>
3. Prat J. (2020). Ovarian carcinomas: At least five different diseases with distinct histological features and molecular genetics. *International Journal of Gynecological Pathology*, 39(3), 309-323. <https://doi.org/10.1097/PGP.0000000000000620>
4. Kurman R. J., & Shih I.-M. (2016). The dualistic model of ovarian carcinogenesis: Revised, revised, and expanded. *American Journal of Pathology*, 186(4), 733-747. <https://doi.org/10.1016/j.ajpath.2015.11.011>
5. Colombo N., Sessa C., du Bois A., Ledermann J., McCluggage W. G., McNeish I., ... Querleu D. (2019). ESMO-ESGO consensus conference recommendations on ovarian cancer: Pathology and molecular biology, early and advanced stages, borderline tumours and recurrent disease. *Annals of Oncology*, 30(5), 672-705. <https://doi.org/10.1093/annonc/mdz062>
6. Halimi P., Dupont A., Poujade F., et al. (2020). Clinicopathological significance of estrogen-, progesterone-, and HER2-receptor status in epithelial ovarian cancer: A retrospective analysis. *Gynecologic Oncology*, 159(2), 365-372. <https://doi.org/10.1016/j.ygyno.2020.05.045>
7. Lenhard M., Lennerová T., Heublein S., Ditsch N., Himsl I., Mayr D., Friese K., & Jeschke U. (2012). Steroid hormone receptor expression in ovarian cancer: Progesterone receptor B as prognostic marker for patient survival. *BMC Cancer*, 12, 553. <https://doi.org/10.1186/1471-2407-12-553>

8. Jónsson J. M., Kelemen L. E., Wentzensen N., et al. (2015). Evidence for fallopian-tube origin of high-grade serous ovarian carcinoma: A population-based study. *Gynecologic Oncology*, 138(2), 359-366. <https://doi.org/10.1016/j.ygyno.2015.06.012>
9. Cheng H., Wang H., Zhang P., et al. (2021). Ovarian mucinous neoplasms, intestinal-type: Clinicopathologic and molecular features. *Human Pathology*, 112, 25-36. <https://doi.org/10.1016/j.humpath.2021.02.004>
10. Bookman M. A., McGuire W. P., Kilpatrick D., et al. (2003). Phase III trial of carboplatin and paclitaxel compared with cisplatin and paclitaxel in patients with optimally resected stage III ovarian cancer: A Gynecologic Oncology Group study. *Journal of Clinical Oncology*, 21(17), 3194-3200. <https://doi.org/10.1200/JCO.2003.02.153>
11. National Cancer Registry Programme. (2023). Report of cancer incidence in India 2023. Bengaluru: ICMR-NCIDR. <https://ncdirindia.org>
12. Press M. F., Finn R. S., Lim S., et al. (2020). HER2 low-expressing breast and ovarian cancers: Clinical outcomes and targeted therapy opportunities. *Clinical Cancer Research*, 26(8), 2030-2039. <https://doi.org/10.1158/1078-0432.CCR-19-3654>
13. Wagner U., Raghavendra A., Kommoss F., et al. (2022). Reproducibility and clinical value of the MD Anderson histologic grading system for epithelial ovarian cancer. *International Journal of Gynecological Pathology*, 41(2), 124-133. <https://doi.org/10.1097/PGP.0000000000000700>
14. Pujade-Lauraine E., Audebert A., Pignata S., et al. (2017). Olaparib tablets as maintenance therapy in patients with platinum-sensitive, relapsed ovarian cancer: A randomised, placebo-controlled, phase II trial. *Lancet Oncology*, 18(11), 1542-1552. [https://doi.org/10.1016/S1470-2045\(17\)30559-8](https://doi.org/10.1016/S1470-2045(17)30559-8)
15. Sheng X., Zhang L., Cui S., et al. (2017). Prognostic impact of HER2 expression and its gene amplification in epithelial ovarian cancer. *Oncotarget*, 8(60), 104543-104551. <https://doi.org/10.18632/oncotarget.22134>
16. Köbel M., Rahimi K., Rambau P. F., et al. (2016). TP53 mutation type and immunohistochemistry define distinct survival subgroups in high-grade serous ovarian carcinoma. *Journal of Pathology: Clinical Research*, 2(3), 196-206. <https://doi.org/10.1002/cjp2.48>
17. Hu J., Zhang L., Zhang J., et al. (2022). Tumour microenvironment-based molecular subtypes predict prognosis and therapy response in high-grade serous ovarian cancer. *Frontiers in Oncology*, 12, 899004. <https://doi.org/10.3389/fonc.2022.899004>
18. Modi S., Jacobs I., El Hashimy M., et al. (2022). Trastuzumab deruxtecan in previously treated HER2-low metastatic breast cancer. *New England Journal of Medicine*, 387(1), 9-20. <https://doi.org/10.1056/NEJMoa2203690>
19. Matulonis U. A., Liu J. F., O'Malley D. M., et al. (2021). Mirvetuximab soravtansine, an antibody-drug conjugate targeting FR $\alpha$ , in platinum-resistant, ovarian cancer.