E-ISSN 2250-0944
ISSN 2250-1150
doi:10.31838/ijprt/15.2.59

Research Article

A Prospective Study of Circumcision by Plastibel Technique in Neonates and Infants

Dr. Suresh Patil[1], Dr. Sangmeshwar Patil[2], Dr. Abdul Khalique[3]
[1]Professor, Gen Surg, Mahadevappa Rampure Medical College, Gulbarga.
[2]Associate Professor, General Surgery, Mahadevappa Rampure medical college, Gulbarga.
[3]3rd year Post Graduate, General Surgery 529 Mahadevappa Rampure medical college, Gulbarga.
Email: [3]zeeshanmalik565@gmail.com
Received: 12.05.25, Revised: 14.06.25, Accepted: 16.07.25

ABSTRACT

Background: Male circumcision (MC) is among the oldest surgical procedures, historically practiced across several continents for cultural, religious, and medical reasons. Plastibel circumcision has gained popularity due to its relative simplicity, reduced complication profile, and suitability for use under local anesthesia. Despite these advantages, complications such as bleeding, infection, and delayed plastibel separation are reported. Neonates are believed to experience fewer complications and faster recovery due to thinner prepuce and simpler anatomy compared with older infants.

Methods: We conducted a prospective study of 488 neonates and infants undergoing plastibel circumcision for cultural or religious indications at the Department of General Surgery, Basaveshwar Teaching and General Hospital, attached to M.R. Medical College, Kalaburagi, between January 2023 and March 2024. Children with congenital penile abnormalities, deranged coagulation profiles, or unstable medical conditions were excluded. Perioperative details including operation time, plastibel device separation day, and postoperative complications were recorded. Follow-up visits were scheduled on post-procedure day 3 and the day of plastibel separation.

Results: Of 488 participants, 66 (13.52%) were neonates and 422 (86.47%) were infants. Mean operative time was 6±2 minutes, and the plastibel fell off at a mean of 6.2 days (range 3–12 days). Neonates showed a shorter mean ring separation time compared with older infants. Successful plastibel circumcision without complications was observed in 408 (83.6%) cases, while 80 (16.4%) experienced minor complications. Delayed ring separation and mild bleeding were the most commonly observed adverse events.

Conclusion: Plastibel circumcision in neonates and infants is a safe, quick, and effective procedure with a favorable complication profile. Neonates generally demonstrate fewer complications and earlier ring separation than older infants, underscoring the potential benefits of early circumcision.

Keywords: Male circumcision, Plastibel technique, Neonates, Infants, Complications, Ring separation

INTRODUCTION

Male circumcision (MC) has a long history and remains one of the most frequently performed surgical procedures worldwide, with estimates suggesting that approximately one-third of the global male population is circumcised for various reasons [1]. Traditionally, this procedure has been practiced throughout most of Africa, parts of Asia, Australia, South and Central America, and regions of North America. In many cultures, it is performed as a rite of passage or for religious observance. Clinically, male circumcision is undertaken to address certain foreskin-related pathologies such as phimosis, paraphimosis, recurrent balanoposthitis, and persistent urinary tract infections [2].

A variety of surgical techniques exist, including the conventional dorsal slit method, sleeve resection, and clamp-based procedures. Among clamp-based techniques, Gomco, Mogen, and Plastibel are commonly utilized. The Plastibel method has gained prominence for its simplicity and reproducibility, especially in neonates and infants [3]. It involves placing a small plastic ring, called a plastibel, over the glans penis. The foreskin is pulled over the ring and secured with a tight suture in the plastic ring's groove, after which the excess foreskin is trimmed. This suture compresses the tissue, causing ischemic necrosis distal to the ligature. Eventually, the plastibel ring detaches—usually within 3 to 10 days—leaving a circumferential wound that heals relatively quickly [2,4–6].

The procedure is often performed on newborns for religious or cultural reasons; however, it is also used as a medical intervention for individuals prone to recurrent infections or when phimosis does not respond to conservative management [2,6]. Circumcision

is contraindicated in neonates or infants with hypospadias, epispadias, ambiguous genitalia, or in those who are medically unstable. Premature infants or those with significant comorbidities are generally not suitable candidates for elective circumcision until their overall health stabilizes [7].

A key advantage of plastibel circumcision is that it often requires only local anesthesia, thereby reducing exposure to potential risks associated with general anesthesia in this young population. Moreover, shorter operative time and the ring's spontaneous separation without the need for suture removal make the procedure parent-friendly. Nevertheless, complications, though uncommon, can occur. These include bleeding, infection, delayed plastibel separation, ring displacement, and extremely rarely, more severe issues such as glans ischemia. Existing literature suggests neonates tend to have fewer complications compared with older infants, possibly due to thinner preputial layers and less robust tissue [1,2,6].

This study aims to prospectively evaluate outcomes and complications of plastibel circumcision in neonates and infants under one year of age. We investigate operative times, ring separation, and the incidence of complications to determine whether early circumcision in neonates may confer a more favorable risk profile than in older infants.

MATERIALS AND METHODS

Study Design and Setting: A prospective study was conducted at the Department of General Surgery, Basaveshwar Teaching and General Hospital, attached to M.R. Medical College, Kalaburagi, from January 2023 through March 2024.

Participants: A total of 488 male children under one year of age were included. Among them, 66 (13.52%) were neonates (0–4 weeks old), and 422 (86.47%) were infants (5 weeks to 12 months old). Children with congenital abnormalities such as hypospadias, deranged coagulation profiles, or critical medical conditions were excluded.

Preoperative Preparation and Consent: All parents or guardians were counseled about the benefits and potential risks of the plastibel procedure. Informed written consent was obtained. Participants were instructed to withhold breastfeeding for at least two hours prior to surgery.

Surgical Technique: Under aseptic conditions, a penile ring block was administered using 1 mL of 2% lignocaine without adrenaline via an insulin syringe at the base of the penis. After a 15-minute waiting period to ensure adequate anesthesia, the surgical field was prepped with povidone-iodine solution. The foreskin was retracted gently, and adhesions between the glans and foreskin were released using arterial forceps. Residual smegma was cleaned thoroughly.

A plastibel of an appropriate size (typically between 1.3 and 1.5 cm for neonates and young infants) was selected. Two hemostats were placed at the tip of the foreskin at the 3 and 9 o'clock positions. The foreskin was then incised longitudinally along its dorsal aspect to facilitate placing the plastibel securely over the glans. The foreskin was pulled forward over the plastibel, and a linen thread ligature was tightly secured in the groove of the plastibel, effectively crushing the preputial tissue. The redundant foreskin was trimmed, and the plastic handle on the plastibel was snapped off.

Postoperative Care and Follow-Up: Oral analgesics were prescribed, and a topical antibiotic ointment was applied to the wound. Parents were educated on how to care for the plastibel, maintain hygiene, and monitor for excessive bleeding or signs of infection. Follow-up visits were scheduled on postoperative day 3 and on the day the plastibel device fell off. If the ring did not separate by two weeks, the child was re-evaluated. Manual removal of the ring was performed under local anesthesia when clinically indicated.

Outcomes and Data Analysis: Key outcome measures included operative time, plastibel ring separation day, and incidence of early (≤14 days) and late (>14 days) complications. Descriptive statistics were used to summarize patient demographics and outcome variables. The study was approved by the institutional ethics committee.

RESULTS

Overall Findings: During the study period, 488 male children fulfilling the inclusion criteria underwent plastibel circumcision. Of these, 66 (13.52%) were neonates (0–4 weeks) and 422 (86.47%) were older infants (5–52 weeks). The mean age among neonates was 18±2 days, whereas for infants it was 4.0±0.5 months.

Mean body weight ranged from 2.2 to 6.8 kg (mean 4.7 kg).
Most children required plastibel sizes of 1.3 or 1.5 cm. The mean duration of the procedure was 6±2 minutes. The average time for plastibel separation across all participants was 6.2 days (range 3–12 days). Notably, neonates had faster ring separation (approximately 3–7 days) compared with the infant group (5–12 days).

Complication Rates and Types: A successful plastibel circumcision without any complication was recorded in 408 (83.60%) cases. Minor complications occurred in 80 (16.4%) children; 3 (4.54%) were neonates, and 77 (18.24%) were older infants. The most frequent complication was delayed ring separation, documented in 28 (5.7%) cases, including 2 neonates and 26 infants. Bleeding (ranging from mild oozing to slightly more persistent bleeding) was reported in 24 (4.9%) children, with 1 neonate and 23 infants affected. Localized superficial infection requiring topical antibiotics was observed in 14 (2.9%) children (2 neonates, 12 infants). Proximal migration of the plastibel ring occurred in 10 children (2 neonates, 8 infants). Inadequate skin removal was noted in 4 infants, necessitating minor revision or further follow-up. No major complications such as glans necrosis or severe infection were recorded.

Table 1: Demographic Profile of Study Participants

Parameter	Neonates (n=66)	Infants (n=422)	Total (n=488)
Mean Age	18±2 days	4.0±0.5 months	-
Age Range	0–4 weeks	5 weeks–12 mos	0–12 mos
Mean Weight	3.0±0.5 kg	5.0±1.0 kg	4.7 kg (2.2–6.8)
Plastibel Size (1.3 cm)	40 (60.6%)	220 (52.1%)	260 (53.3%)
Plastibel Size (1.5 cm)	26 (39.3%)	202 (47.9%)	228 (46.7%)

Table 2: Operative and Postoperative Parameters

Parameter	Neonates (n=66)	Infants (n=422)	Combined (n=488)
Mean Operative Time (min)	5±2	6±2	6±2
Mean PD Separation (days)	4–7	5–12	6.2 (3–12)
Follow-up (days)	14	14	14

(PD – Plastibel device)

Table 3: Distribution of Complications

Complication	Neonates (n=66)	Infants (n=422)	Total (%) (n=488)
Delayed Ring Separation	2 (3.03%)	26 (6.16%)	28 (5.74%)
Bleeding	1 (1.51%)	23 (5.45%)	24 (4.92%)
Localized Infection	2 (3.03%)	12 (2.84%)	14 (2.87%)
Proximal Ring Migration	2 (3.03%)	8 (1.89%)	10 (2.04%)
Inadequate Skin Removal	0	4 (0.95%)	4 (0.82%)
Total	7 (10.60%)*	73 (17.29%)*	80 (16.39%)

* Some infants had more than one minor complication.

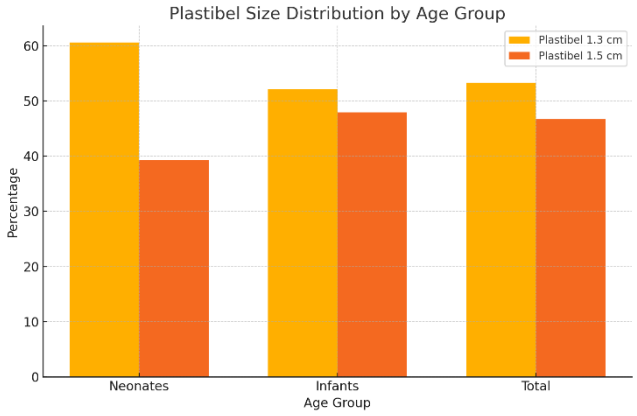

Figure 1: Schematic diagram of the Plastibel technique showing the ring application, ligature, and subsequent excision of redundant foreskin.

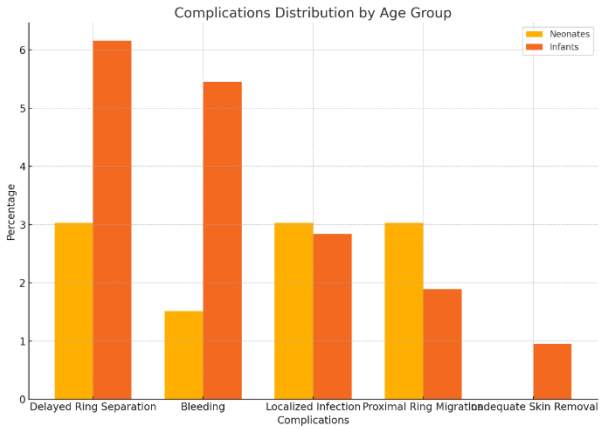

Figure 2: Clinical Photograph (Schematic Representation) Of Typical Ring Placement In A Neonate And Day 5 Appearance Post-Procedure.

CIRCUMCISION DEVICE


CIRCUMCISION
DEVICE
Size : 1.3 cms


CIRCUMCISION
DEVICE
Size : 1.5 cms


CIRCUMCISION
DEVICE
Size : 1.7 cms

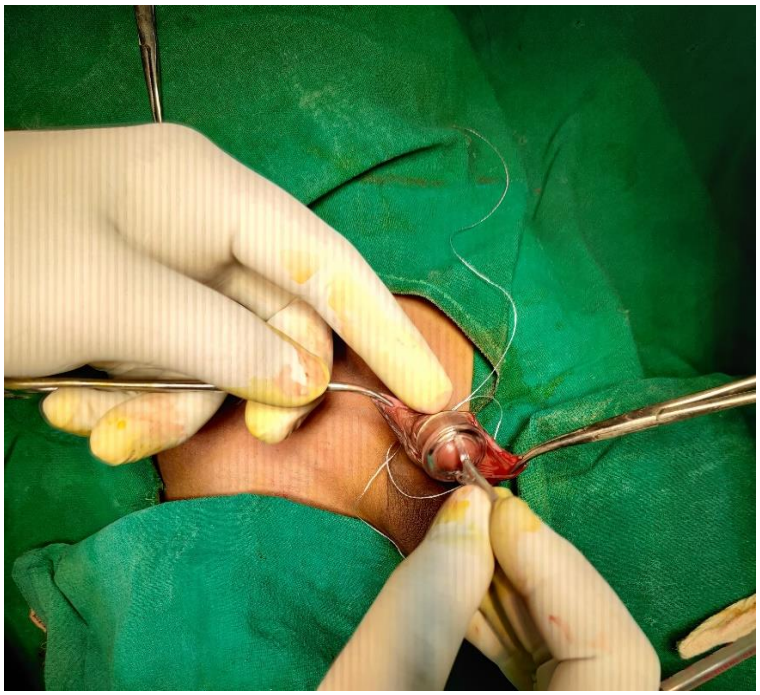

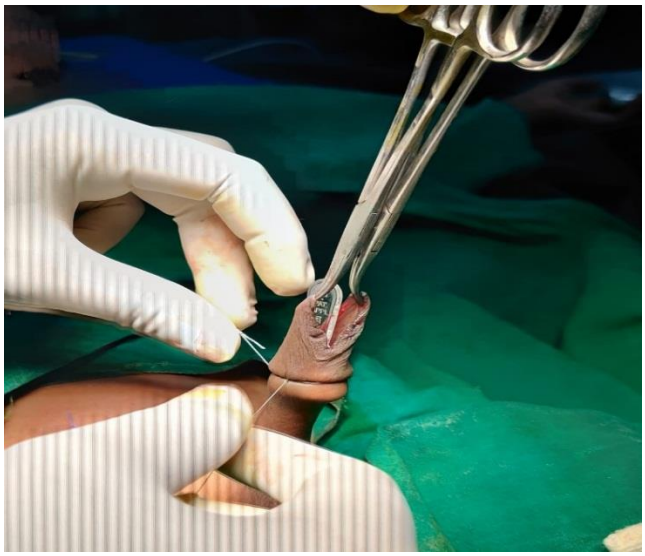

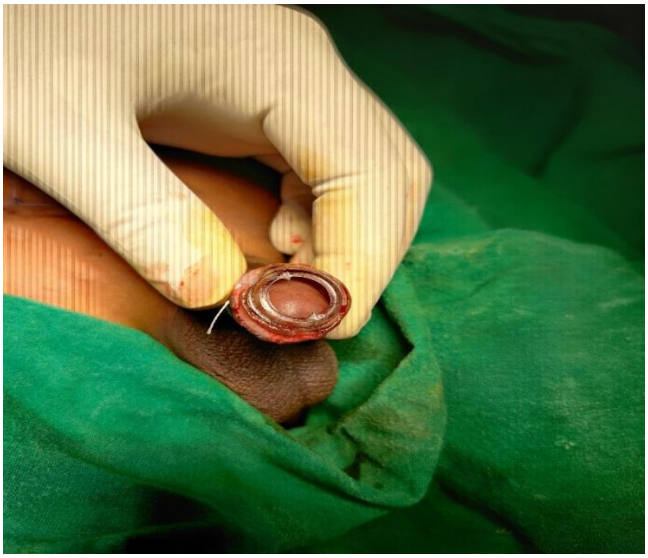

DISCUSSION

This prospective study investigated the outcomes of plastibel circumcision in neonates and infants under one year of age, highlighting its advantages, including shorter operative time, simpler anesthesia requirements, and a relatively low complication rate. Our results are consistent with previous literature indicating that neonates experience earlier plastibel ring separation due to the thinner nature of their foreskin [8–12]. In our cohort, the ring generally fell off between the third and twelfth postoperative day, with neonates showing a mean of about four to seven days.

Notably, 16.4% of children in our study experienced minor complications—most commonly delayed ring separation—slightly higher than some prior reports suggesting a 2–3% complication rate [14,16–18]. However, these studies often employ different definitions of what constitutes a "complication," and many exclude minor issues that resolve without intervention. Bleeding was the second most frequent issue, affecting 4.9% of cases overall. This percentage aligns with literature citing that minor bleeding, controlled with simple maneuvers, is not uncommon in plastibel circumcision [4,9,13].

Infections were limited to 2.9% of subjects, reflecting the importance of meticulous aseptic technique and post-procedure care. The local environment, especially for neonates whose diapering practices may predispose them to higher moisture levels, can be a risk factor for infection [15]. Proximal ring migration was noted in 10 cases, generally attributable to inadequate sizing or insufficiently tight securing of the foreskin. This underscores the significance of proper device selection; a bell that is too large may fail to stay in place, whereas a bell that is too small can compress the glans, potentially leading to pain or edema [16].

Interestingly, the low rate of complications in neonates supports the view that earlier circumcision may be advantageous [7]. Thinner tissue, quicker healing capacity, and minimal mobility of the neonate all contribute to better outcomes. Our findings also affirm that a carefully applied ring block with lidocaine is effective for pain control, reducing the need for more invasive anesthetic techniques [3].

Although no major complications were encountered, severe events such as glans necrosis, severe infections, or urethral injuries have been rarely reported by other investigators [4,14]. Constant vigilance, correct technique, appropriate patient selection, and close postoperative monitoring are essential to prevent serious morbidity.

Overall, our study underscores the safety and efficacy of plastibel circumcision for male children under one year of age, with neonates experiencing fewer and less severe complications. This aligns with the broader literature advocating early circumcision where cultural, religious, or medical indications exist. Further large-scale, multi-center trials could help refine device selection guidelines, standardize complication reporting, and optimize postoperative care protocols.

CONCLUSION

Plastibel circumcision in neonates and infants is a safe, quick, and easily performed technique associated with low complication rates. Neonates in particular display faster plastibel separation and fewer complications, likely due to thinner preputial tissue and reduced movement. Even when complications arise—most commonly delayed ring separation or mild bleeding—they are typically minor and easily managed. Selecting an appropriately sized plastibel ring and meticulous surgical technique are crucial for ensuring favorable outcomes. Given these findings, early circumcision appears to be a viable and parent-acceptable option for families opting for this procedure due to cultural, religious, or clinical reasons.

REFERENCES

1. Cox G, Morris BJ: Why circumcision: from prehistory to the twenty-first century. Surgical Guide to Circumcision. Bolnick D, Koyle M, Yosha A (eds). Springer, London; 2012:243-59. 10.1007/978-1-4471-2858-8_21
2. Prabhakaran S, Ljuhar D, Coleman R, Nataraja RM: Circumcision in the paediatric patient: a review of indications, technique and complications. J Paediatr Child Health. 2018;54:1299-307. 10.1111/jpc.14206
3. Jimoh BM, Odunayo IS, Chinwe I, Akinfolarin OO, Oluwafemi A, Olusanmi EJ: Plastibel circumcision of 2,276 male infants: a multi-centre study. Pan Afr Med J. 2016;23:35. 10.11604/pamj.2016.23.35.7841
4. Weiss HA, Larke N, Halperin D, Schenker I: Complications of circumcision in male neonates, infants and children: a systematic review. BMC Urol. 2010;10:2. 10.1186/1471-2490-10-2

5. Lerman SE, Liao JC: Neonatal circumcision. Pediatr Clin North Am. 2001;48:1539-57. 10.1016/s0031-3955(05)70390-4
6. Morris BJ, Moreton S, Krieger JN: Critical evaluation of arguments opposing male circumcision: A systematic review. J Evid Based Med. 2019;12:263-90. 10.1111/jebm.12361
7. Moosa FA, Khan FW, Rao MH: Comparison of complications of circumcision by "Plastibel Device Technique" in male neonates and infants. J Pak Med Assoc. 2010;60:664-7.
8. Barrie H, Huntingford PJ, Gough MH: The Plastibel technique for circumcision. BMJ. 1965;2(5456):273-5.
9. Duncan ND, Dundas SE, Brown B, Pinnock-Ramsaran C, Badal G: Newborn circumcision using the Plastibel device: an audit of practice. West Indian Med J. 2004;53:23-6.
10. Jimoh BM, Odunayo IS, Chinwe I, Akinfolarin OO, Oluwafemi A, Olusanmi EJ: Plastibel circumcision of 2,276 male infants: a multi-centre study. Pan Afr Med J. 2016;23:35.
11. Mousavi SA, Salehifar E: Circumcision complications associated with the Plastibel device and conventional dissection surgery: A trial of 586 infants of ages up to 12 months. Adv Urol. 2008;2008:606123.
12. Palit V, Menebhi DK, Taylor I, Young M, Elmasry Y, Shah T: A unique service in UK delivering Plastibel circumcision: review of 9-year results. Paediatr Surg Int. 2007;23:45-8.
13. Lazarus J, Alexander A, Rode H: Circumcision complications associated with the Plastibel device. S Afr Med J. 2007;97:192-3.
14. Manji KP: Circumcision of the young infant in a developing country using Plastibel. Ann Trop Paediatr. 2000;20:101-4.
15. Palit V, Menebhi DK, Taylor I, Young M, Elmasry Y, Shah T: A unique service in UK delivering Plastibel circumcision: review of 9-year results. Paediatr Surg Int. 2007;23:45-8.